INDEX COPERNICUS INTERNATIONAL

CASE STUDY

Case report of a 72-year-old man with a giant neck lipoma

Opis przypadku 72-letniego mężczyzny z olbrzymim tłuszczakiem szyi

Authors' Contribution:
A – Study Design
B – Data Collection
C – Statistical Analysis
D – Data Interpretation
E – Manuscript Preparation
F – Literature Search
G – Funds Collection

Jakub Zblewski[1ABCDEF], Krzysztof Dalke[1,2ACDF], Oliwia Zblewska[3ABEF], Tomasz Bartoszewski[1ACDF]

[1]Otolaryngology Department, Władysław Biegański Regional Specialist Hospital in Grudziadz, Poland
[2]Faculty of Medicine, Bydgoszcz University of Science and Technology, Bydgoszcz, Poland
[3]Faculty of Medicine, Collegium Medicum im. Ludwika Rydygiera in Bydgoszcz University Nicolaus Copernicus in Torun, Bydgoszcz, Poland

Article history: Received: 11.05.2025 Accepted: 03.08.2025 Published: 22.08.2025

ABSTRACT:

Introduction: Lipomas (lat. *lipoma*) are the most common benign mesenchymal tumors, usually located subcutaneously and reaching small sizes. In rare cases, giant lipomas (lat. *lipoma gigantica*) may develop, with a diameter exceeding 10 cm and a mass greater than 1000 g. Giant lipomas in the head and neck region represent a particular diagnostic and therapeutic challenge.

Case report: We present the case of a 72-year-old patient with a giant neck tumor that had been developing over many years. The mass was painless on palpation, with the main bulk located on the left side of the neck and extending posteriorly. The lesion was surgically removed in its entirety — the tumor measured 35 × 28 × 11 cm and weighed 2.70 kg. The postoperative course was uneventful. Histopathological examination confirmed the presence of a lipoma without atypia. This case illustrates successful surgical management of a giant neck lipoma, which constituted both an aesthetic and functional problem for the patient.

Discussion: The diagnosis of lipomas is based on physical examination and imaging studies. Surgical excision remains the treatment of choice, particularly in the case of giant lipomas and/or those causing mechanical symptoms. A key aspect is differentiation from liposarcoma (lat. *liposarcoma*), a malignant tumor requiring a different therapeutic approach. Recurrence of lipomas is rare and usually results from incomplete resection. Postoperative follow-up is important, especially in cases of large lesions or those with an atypical course.

Conclusions: Giant lipomas of the neck are rare, but they may cause significant body deformity and impair normal function. Proper diagnosis, careful surgical planning, and histopathological analysis are essential to achieve satisfactory therapeutic outcomes.

KEYWORDS: giant lipoma, lipoma, liposarcoma, neck tumor

STRESZCZENIE:

Wstęp: Tłuszczaki (łac. *lipoma*) są najczęstszymi łagodnymi nowotworami mezenchymalnymi, zwykle lokalizującymi się podskórnie i osiągającymi niewielkie rozmiary. W rzadkich przypadkach dochodzi do rozwoju tłuszczaków olbrzymich (łac. *lipoma gigantica*), których średnica wynosi ponad 10 cm, a masa przekracza 1000 g. Tłuszczaki olbrzymie w obrębie głowy i szyi stanowią szczególne wyzwanie diagnostyczno-terapeutyczne.

Opis przypadku: Przedstawiono przypadek 72-letniego pacjenta, u którego stwierdzono olbrzymi guz szyi rozwijający się przez wiele lat. Guz niebolesny palpacyjnie, główna masa guza znajdowała się po stronie lewej szyi i przechodziła na jej tył. Chirurgicznie usunięto zmianę w całości – guz o wielkości 35 x 28 x 11 cm i wadze 2,70 kg. Przebieg pooperacyjny bez powikłań. Badanie histopatologiczne potwierdziło obecność tłuszczaka bez cech atypii. Przypadek ten ilustruje skuteczne leczenie chirurgiczne olbrzymiego tłuszczaka szyi, stanowiący zarówno defekt estetyczny, jak i funkcjonalny dla pacjenta.

Dyskusja: Diagnostyka tłuszczaków opiera się na badaniu fizykalnym i obrazowym. Zabieg chirurgiczny pozostaje metodą z wyboru w leczeniu tłuszczaków, szczególnie tych olbrzymich i/lub wywołujących objawy mechaniczne. Kluczowe jest różnicowanie z tłuszczakomięsakiem (łac. *liposarcoma*), który stanowi zmianę złośliwą i wymaga odmiennego postępowania terapeutycznego. Nawrót tłuszczaka jest rzadki i zwykle wynika z niecałkowitej resekcji zmiany. Istotna jest kontrola pooperacyjna pacjentów, szczególnie w przypadkach zmian dużych lub o nietypowym przebiegu.

Wnioski: Tłuszczaki olbrzymie szyi są rzadko spotykane, ale prowadzą do znacznych deformacji ciała i utrudniają funkcjonowanie organizmu. Właściwa diagnostyka, zaplanowanie zabiegu operacyjnego i analiza histopatologiczna są niezbędne dla osiągnięcia zadowalających efektów terapeutycznych.

SŁOWA KLUCZOWE: guz szyi, tłuszczak, tłuszczak olbrzymi, tłuszczakomięsak

ABBREVIATIONS

CT – computed tomography
MEN1 – multiple endocrine neoplasia type 1
MRI – magnetic resonance imaging
US – ultrasound
X-ray – radiograph

INTRODUCTION

Lipomas (lat. *lipoma*) are the most common benign soft tissue tumors originating from mature adipose tissue. They occur in approximately 1% of the population and can develop in almost any part of the body, although they are most often located subcutaneously on the back, shoulders, arms, thighs, and chest. These lesions are usually small, well-circumscribed, and asymptomatic. Lipomas in the head and neck region are less common, and their presence may lead to compressive symptoms as well as significant aesthetic deformities, particularly when they reach large dimensions [1–4].

Giant lipomas (lat. *lipoma gigantica*) are defined as lesions exceeding 10 cm in diameter or weighing more than 1000 g [5]. Their slow, often long-term growth may be overlooked, particularly in patients with limited access to medical care or cognitive impairment. Despite their benign nature, these lesions require thorough differential diagnosis, especially in the context of excluding liposarcoma (lat. *liposarcoma*), which requires a different therapeutic approach and carries a less favorable prognosis [1].

In this paper, we present the case of a 72-year-old patient with intellectual disability, in whom a giant neck lipoma was diagnosed and successfully treated surgically. The case serves as a starting point for a broader discussion on the diagnosis, differential



Fig. 1. Patient before surgery, views from posterior, lateral, and anterior perspectives.

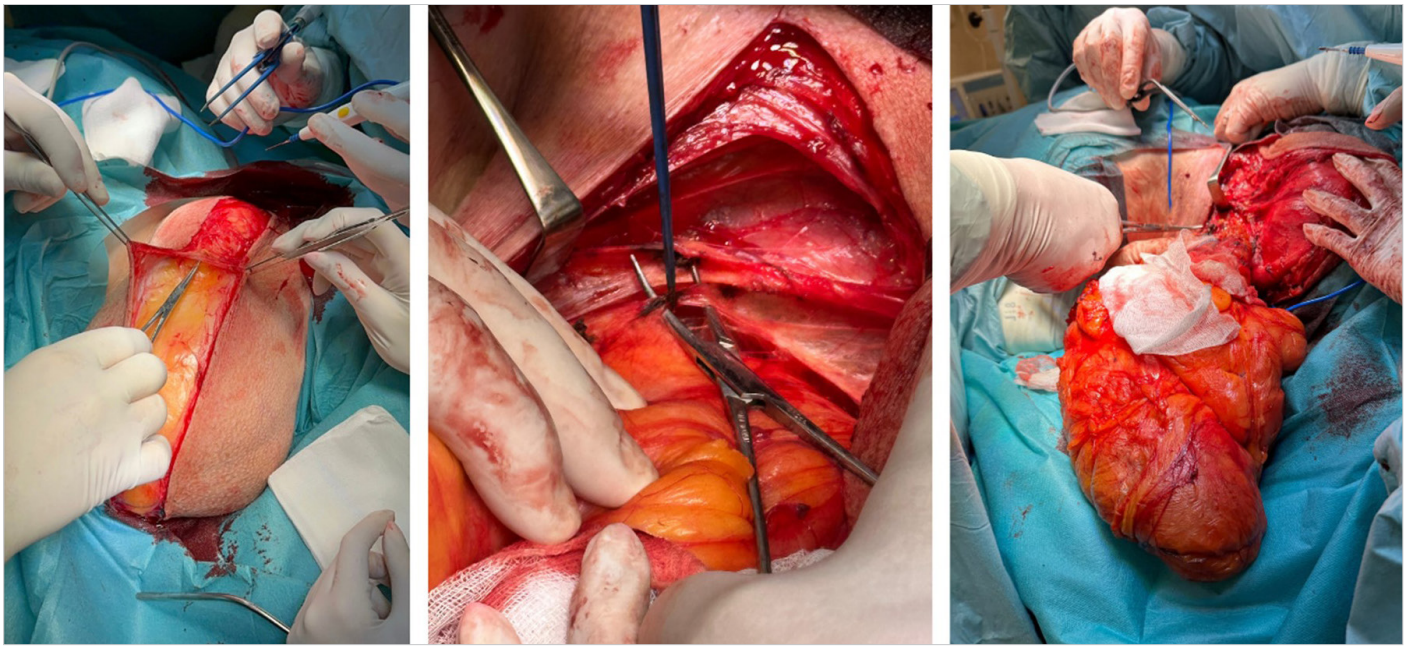

Fig. 2. Sequential stages of the surgical procedure.

considerations, and therapeutic management of giant lipomas in atypical locations.

CASE REPORT

A 72-year-old patient was admitted to the Psychiatric Ward due to agitation following the death of his closest family member, who had previously been his legal guardian. The patient had severe intellectual disability and was under full legal incapacitation. He had a history of bacterial meningitis several years earlier. Until admission, he had not been treated for any chronic conditions. Medical history could not be obtained directly from the patient. He was a resident of a nursing home. During hospitalization, the court appointed a new legal guardian – a social worker. During his stay, the patient was referred for an otolaryngology consultation due to a giant neck mass that had been enlarging for many years. The skin over the lesion was intact, with no visible ulcerations. The mass was painless on palpation, with the main bulk located laterally on the left side of the neck and extending posteriorly (Fig. 1.). Laboratory tests revealed no abnormalities. The following imaging studies were performed:

- neck ultrasound (US): Non-diagnostic due to lack of patient cooperation;
- contrast-enhanced neck CT: In the left lateral neck, extending into the posterior cervical region, a large soft-tissue mass was identified with fat density (approx. –110 Hounsfield units), consistent with a lipoma. The lesion measured approximately 25 × 17 × 30 cm (height × depth × width). Within the mass, narrow fibrous septa were visible, as well as several round to oval structures, mainly in its inferior pole, ranging from 1 to 8 cm in size, filled with adipose tissue and with partially calcified walls. The adjacent cervical muscles were preserved. No significant cervical lymphadenopathy was noted. The administered contrast agent, despite a long delay before image acquisition (~100 s), did not enhance the carotid vessels;
- chest X-ray: Lung fields without parenchymal consolidations. Cardiac silhouette within normal limits. Pleural spaces clear.

Based on the physical examination and imaging findings, the patient was qualified for surgical treatment at the Department of Otolaryngology, Regional Specialist Hospital in Grudziądz.

Under general anesthesia, the patient was positioned supine. A transverse incision of approximately 35 cm was made over the largest protrusion of the tumor, exposing the lipoma capsule. The encapsulated mass was partially dissected and partially enucleated from the surrounding adipose tissue (Fig. 2.). The tumor, measuring 35 × 28 × 11 cm and weighing 2.70 kg, was completely removed (Fig. 3.). Excess neck skin was then excised, and a neck plasty was performed. A suction drain was placed (Fig. 4.–5.).

The procedure and postoperative course were uneventful. The drain was removed two days after surgery. Wound healing was normal.

The patient was discharged from the hospital in good general condition, free of pain, on the sixth postoperative day. At a follow-



Fig. 3. Excised tumor, measuring approximately 35 × 28 × 11 cm, weighing 2.70 kg.

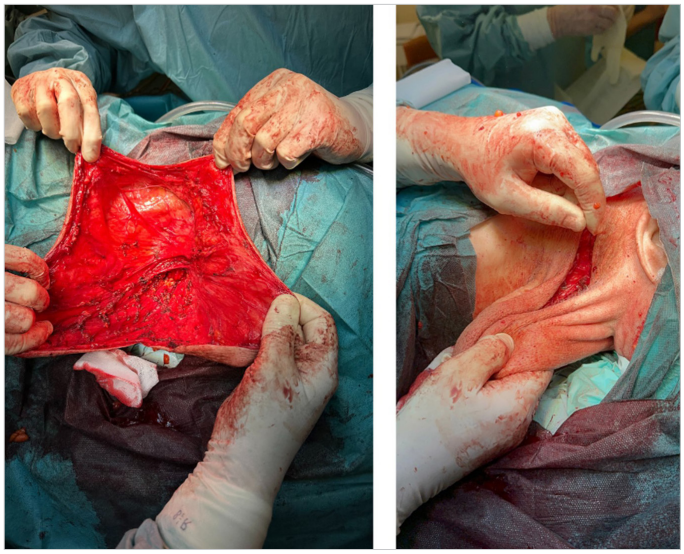

Fig. 4. Excess skin before plasty, after tumor excision.

-up visit on the tenth postoperative day, in the presence of the patient's legal guardian, sutures were removed. Wound healing was normal, with no signs of infection, and the cosmetic outcome was satisfactory (Fig. 6.).

The specimen submitted for histopathological examination confirmed the diagnosis of lipoma – a fatty tumor with foci of necrotic changes, accompanied by reactive granulation tissue, fibrosis, and calcifications, without cellular atypia. The diagnosis was established as a benign giant neck lipoma.

DISCUSSION

Lipomas are the most common mesenchymal tumors. They are benign, usually round or oval soft tissue masses that typically grow



Fig. 5. Patient in the operating room after tumor excision and neck skin plasty.



Fig. 6. Patient on the 10th postoperative day, status after suture removal.

just beneath the skin surface. Lipomas are composed of mature white adipose tissue [1, 6]. They are well circumscribed from surrounding tissue and range in color from yellow to orange. Although richly vascularized, the vessels are often compressed by distended adipocytes. Lipomas occur in approximately 1% of the population [1].

Lipomas can develop in any part of the body, but they most commonly occur on the back, anterior chest wall, arms, shoulders, and thighs. Only about 13–25% of lipomas are located in the head and neck region, with the posterior neck being the most frequent site [1–3, 7]. Based on their depth, lipomas are classified as subcutaneous, subfascial, deep internal or visceral, as well as lipomas of other specified or unspecified body regions [1].

They most often appear between the ages of 40 and 60, but can develop at any age [4]. They affect both sexes, though they are slightly more common in women [2, 3]. Typically, lipomas present as solitary tumors, though some individuals may develop multiple lesions. They are usually soft and painless. Discomfort generally arises from their mass effect – when they compress a nerve, exert traction on surrounding tissues, or are located near a joint [5]. In cases of large tumors, they may cause compressive symptoms such as dysphagia or dyspnea. Additionally, they may be complicated by bleeding from pressure ulcers of the overlying skin [2]. Intracranial lipomas can lead to diplopia, hydrocephalus, seizures, hearing impairment, and vertigo [1, 8]. Lipomas often represent an aesthetic defect, which can significantly affect the patient's psychological well-being.

Lipomas typically grow slowly and reach sizes ranging from a few to several centimeters. Particularly large lipomas are referred to as giant lipomas, defined as lesions with a diameter exceeding 10 cm or a mass greater than 1000 g [5].

Diagnosis of lipomas is primarily based on physical examination. On palpation, the mass is soft, doughy in consistency, oval, mobile, and usually painless [8]. Imaging studies, while not always necessary for diagnosis, are valuable, especially for evaluating deeper lipomas. Ultrasonography can be helpful, but computed tomography (CT) and magnetic resonance imaging (MRI) provide more precise assessment of size, depth, compressive features, and the relationship to nearby nerves and blood vessels [1, 5]. On a CT scan, a lipoma typically appears as a homogeneous, low--density mass – usually between –50 and –150 Hounsfield units – with no contrast enhancement [2]. The capsule of the lipoma is usually poorly visualized, and the mass may be traversed by multiple fibrous septa. On MRI, a typical lipoma appears as a well--circumscribed, homogeneous fatty mass, hyperintense on both T1- and T2-weighted sequences, with a signal similar to that of subcutaneous fat [5, 9]. Furthermore, the margin of a lipoma is clearly defined on MRI as a "black rim," which allows differentiation of the lipoma from surrounding adipose tissue - something that cannot be reliably achieved on CT images [5]. Another valuable tool is genetic testing, which can aid in establishing the correct diagnosis in complex cases or in differentiating ambiguous lesions. Lipomas may be associated with genetic disorders such as multiple endocrine neoplasia type 1 (MEN1), neurofibromatosis type 1, Wilson's disease, or mitochondrial disorders [1].

In the differential diagnosis of lipomas, the following conditions should be considered: liposarcoma, metastatic tumors, lymphoma, hematoma, abscess, epidermoid cyst, nodular fasciitis, nodular necrosis of subcutaneous fat, erythema nodosum, vascular nodules, rheumatic nodules, sarcoidosis, and Weber-Christian panniculitis [1, 10]. Lipoblastoma is a rare benign fatty tumor that occurs mainly in young children and infants [11]. A rare condition is Madelung's disease, also known as benign symmetric lipomatosis, which is characterized by symmetrical, painless fat deposits around the neck and shoulder girdle [12]. Hibernoma (lat. *hibernoma*) is another rare soft tissue tumor composed of remnants of brown adipose tissue. Hibernomas usually present as asymptomatic masses until the tumor compresses adjacent structures [13–15].

The treatment of choice for lipomas is surgical excision. The procedure typically involves making an incision over the tumor mass and enucleating the lipoma, which is usually facilitated by the

presence of the tumor capsule. In some cases, complete removal may be preceded by liposuction, which allows preliminary reduction of tumor size. Injectable lipolysis can reduce the size of lipomas, but this method does not achieve complete elimination of the lesion [4]. For deeply located lipomas, the type of surgical procedure depends on the lesion's location and the symptoms it causes [1, 4, 16, 17]. Resection of deep-seated or muscle-infiltrating lipomas can be more challenging, with a higher risk of recurrence. In such cases, careful surgical planning and close postoperative monitoring are necessary. Recurrence after lipoma removal is rare and usually occurs due to incomplete resection [4].

Lipomas are benign tumors, but in rare cases they may undergo malignant transformation, for example into liposarcoma. Liposarcoma is a malignant tumor arising from adipose tissue. Unlike a benign lipoma, liposarcoma has the ability to infiltrate surrounding tissues and metastasize and therefore requires definitive treatment. The mean age of patients with lipoma is lower than that of patients with liposarcoma [3]. Warning signs include rapid tumor growth, increased firmness, poor mobility relative to underlying tissue, pain, and invasion of adjacent structures. Liposarcomas usually occur in deeper anatomical layers, and tumors often exceed 11 cm in diameter at initial detection, exerting pressure on neighboring structures and internal organs [3]. Imaging studies and lesion biopsy are useful for differential diagnosis. MRI is highly sensitive for diagnosing liposarcomas and can help distinguish lipoma from liposarcoma by assessing signal intensity [5]. Features of liposarcoma on MRI include nodular appearance, lower fat content, areas of marked enhancement, calcifications, and thickened septa – greater than 2 mm in thickness [3, 5]. Because liposarcomas have high rates of local recurrence, accurate preoperative differentiation between lipoma and liposarcoma is crucial for planning appropriate surgical resection margins [3].

It is therefore important to monitor patients after surgical treatment to enable early detection of potential recurrences, malignant transformation, or complications.

CONCLUSIONS

Giant lipomas are rare but significant soft tissue tumors in the head and neck region. They can cause considerable body deformity and impair normal function. They may also be complicated by bleeding from pressure ulcers of the overlying skin. Accurate diagnosis and treatment require thorough clinical assessment and appropriate imaging studies to evaluate surgical risk. Surgical excision remains the primary treatment method for lipomas. Following resection, detailed histopathological analysis is essential to rule out possible malignant transformation, such as into liposarcoma.

REFERENCES

1. Marzyńska D., Żaba R., Lacka K.: Lipomas: genetic basis of common skin lesions and their occurrence in rare diseases. Postepy Dermatol Alergol., 2023; 40(4): 481–486. doi: 10.5114/ada.2023.129529.
2. Verma S., Varma M., Kala S., Singh R.: Giant lipoma of posterior neck with bleeding decubitus ulcer: a rare entity. J Cutan Aesthet Surg., 2010; 3(2): 119–121. doi: 10.4103/0974-2077.69027.
3. Du A., Wang H., Dai J., Dong Q., Yuan G. et al.: Case report: a case report of excision of a giant lipoma in the posterior neck. Front Oncol., 2024; 14: 1395130. doi: 10.3389/fonc.2024.1395130.
4. Gierlotka A., Wąsowicz B., Kozakiewicz J., Barzyk-Arciszewska A.: Przypadek olbrzymiego tłuszczaka szyi. Forum Med Rodz., 2014; 8(2): 84–87.
5. Kabiri E.H., El Hammoumi M., Bhairis M.: Giant Lipoma of the Anterior Neck and Supraclavicular Region. Eplasty., 2023; 23: QA5.
6. Osuch-Wójcikiewicz E., Bruzgielewicz A., Chęciński P., Szwedowicz P.: Guzy łagodne przestrzeni przygardłowej. Otolaryngol Pol., 2011; 65(5 Suppl): 67–72. doi: 10.1016/S0030-6657(11)70711-9.
7. Rokicki M., Rokicki W.: Tłuszczak karku znacznych rozmiarów. Wiad Lek., 1998; 51(9–10): 450–452.
8. Romano N., Castaldi A.: Imaging of intracranial fat: from normal findings to pathology. Radiol Med., 2021; 126(7): 971–978. doi: 10.1007/s11547--021-01365-5.
9. Eryılmaz M.A., Yücel A., Yücel H., Arıcıgil M.: Cervico-Thoracic Giant Lipoma in a Child. Turk Arch Otorhinolaryngol., 2016; 54(2): 82–85. doi: 10.5152/tao.2016.1620.
10. Matyja G., Dziekan T., Dobrzycki W.: Rzadkie guzy szyi – postępowanie diagnostyczne i lecznicze. Otolaryngol Pol., 2000; 54 Suppl 31: 87–89.
11. Gregor J., Dzielicki J.: Postępowanie diagnostyczne i leczenie chirurgiczne lipoblastoma u dzieci na podstawie własnego doświadczenia. Med Wieku Rozwoj., 2001; 5(3 Suppl 1): 71–74.
12. Magońska-Oleszycka A., Madeyski J.: Rzadki przypadek choroby Madelunga. Otolaryngol Pol., 2002; 56(2): 245–247.
13. Narozny W., Stankiewicz C.: Przypadek zimowiaka szyi. Otolaryngol Pol., 1984; 38(5): 453–455.
14. Krajka K., Sliwińska I.: Hibernoma – guz brunatnej tkanki tłuszczowej. Pol Tyg Lek., 1982; 37(46/47): 1397–1398.
15. Gawlik Z., Czartoszewski A.: A case of brown lipoma. Patol Pol., 1960; 11: 195–200.
16. Szyfter W., Wierzbicka M., Balcerowiak A.: Czy zabiegi endoskopowe stanowią przyszłość chirurgii szyi?. Otolaryngol Pol., 2007; 61(4): 378–382. doi: 10.1016/S0030-6657(07)70447-X.
17. Ziuzio S., Gospodarek T., Bialozyk P., Kubas G., Pajnowski M.: Niepowodzenia diagnostyczne i operacyjne w leczeniu torbieli oraz przetok bocznych i środkowych szyi. Otolaryngol Pol., 1995; 49 Suppl 23: 191–194.

Table of content: https://otorhinolaryngologypl.com/issue/17010 Tables: – Figures: 6 References: 17

Copyright: Some rights reserved: Polish Society of Otorhinolaryngologists Head and Neck Surgeons. Published by Index Copernicus Sp. z o.o.

Competing interests: The authors declare that they have no competing interests.

The content of the journal „Polish Society of Otorhinolaryngologists Head and Neck Surgeons" is circulated on the basis of the Open Access which means free and limitless access to scientific data.

This material is available under the Creative Commons – Attribution-NonCommercial 4.0 International (CC BY-NC 4.0).
The full terms of this license are available on: https://creativecommons.org/licenses/by-nc/4.0/legalcode

Corresponding author: Jakub Zblewski; Otolaryngology Department, Władysław Biegański Regional Specialist Hospital in Grudziadz; Grudziadz, Poland; E-mail: jakubzblewski.med@gmail.com

Cite this article as: Zblewski J., Dalke K., Zblewska O., Bartoszewski T.: Case report of a 72-year-old man with a giant neck lipoma; Pol Otorhino Rev 2025; 14 (4): 1–6; DOI: 10.5604/01.3001.0055.2477