INDEX COPERNICUS INTERNATIONAL

Chorda tympani and its potential for the stabilization of the ossicular chain as based on the experience of the Department of Otolaryngology at the University Hospital in Kraków, Poland

Struna bębenkowa i jej możliwości do wykorzystania w stabilizacji łańcucha kosteczek na podstawie doświadczeń Klinicznego Oddziału Otolaryngologii Szpitala Uniwersyteckiego w Krakowie

Authors' Contribution:
A – Study Design
B – Data Collection
C – Statistical Analysis
D – Data Interpretation
E – Manuscript Preparation
F – Literature Search
G – Funds Collection

Remigiusz Ziarno[1ADE], Magdalena Sobuś[2EF], Aleksandra Grudzień-Ziarno[1AED], Maciej Wiatr[3ABD], Agnieszka Wiatr[3ABD], Sebastian Kocoń[3BDE], Konrad Skórkiewicz[3F], Jacek Składzień[3ABDEF], Jerzy Tomik[1ABDG]

[1]Department of Otolaryngology, University Hospital in Kraków, Poland
[2]Institute of Veterinary Medicine, Nicolaus Copernicus University in Toruń, Poland
[3]Jagiellonian University Medical College, Kraków, Poland

Article history: Received: 23.10.2025 Accepted: 11.12.2025 Published: 11.12.2025

ABSTRACT:

Introduction: Passing through the tympanic cavity, the chorda tympani is supplied from its dedicated vessels and covered by a mucous membrane having the same composition of epithelial cells as that lining the other structures of a healthy tympanic cavity in that area.

Aim: The aim of this paper is to propose the use of the chorda tympani in middle ear surgeries.

Material and methods: A retrospective analysis of the records of patients receiving treatment for chronic otitis media and otosclerosis at the Department of Otolaryngology of the Jagiellonian University Medical College in terms of the operators' use of the chorda tympani to stabilize the reconstructed ossicular chain in chronic otitis media and the head of the prosthesis placed on the long crus of the incus in otosclerosis.

Results: The surgical technique is described, and very good treatment results are presented as suggestions for specific solutions for operators in middle ear surgeries.

Conclusions: Chorda tympani can be used to stabilize the reconstruction of the ossicular chain.

KEYWORDS: eardrum string, stabilization of ossicular chain reconstruction

STRESZCZENIE:

Wstęp: Struna bębenkowa na terenie jamy bębenkowej posiada własne unaczynienie i jest pokryta błoną śluzową o takim składzie komórek nabłonka, jaki mają inne struktury zdrowej jamy bębenkowej w tym miejscu.

Cel: Celem pracy jest zaproponowanie możliwości wykorzystania struny bębenkowej w operacjach ucha środkowego.

Materiał i metody: Dokonano retrospektywnej analizy dokumentacji chorych leczonych w Klinice ORL CMUJ z powodów przewlekłego zapalenia ucha środkowego i otosklerozy pod kątem wykorzystania przez operatorów struny bębenkowej w celu stabilizacji rekonstrukcji łańcucha kosteczek w przewlekłych zapaleniach ucha środkowego oraz główki protezki zakładanej na odnogę drugą kowadełka w otosklerozie.

Wyniki: Autorzy opisują technikę operacyjną i przedstawiają bardzo dobre wyniki leczenia jako propozycje określonych rozwiązań dla operatorów ucha środkowego.

 DOI: 10.5604/01.3001.0055.5022

Wnioski: Struna bębenkowa może być wykorzystana do stabilizacji rekonstrukcji łańcucha kosteczek.

SŁOWA KLUCZOWE: stabilizacja rekonstrukcji łańcucha kosteczek, struna bębenkowa

INTRODUCTION

The chorda tympani is made up of fibers of the intermediate nerve, but not of the motor part of the facial nerve. It retrogradely enters the tympanic cavity from behind, heading forward between the long crus of the incus and the manubrium of the malleolus, at about the level of the junction of the tympanic membrane's pars tensa and pars flaccida, and further to enter the Glaserian fissure [1–5].

Within the tympanic cavity, the chorda tympani is covered by a mucous membrane having the same composition of epithelial cells as that lining the other structures in that area, such as for instance 2–10% of ciliated cells, isolated goblet cells, etc. While this is also the case, for example, in otosclerosis, the composition of the chorda tympani differs from that of its surroundings in cases of chronic inflammatory processes of any etiology affecting the tympanic cavity. Chorda tympani is supplied by its own dedicated vasculature [1–6] (Fig. 1.).

In the early 20th century, the objective of the treatment of chronic otitis was to eliminate pathology that threatened the patient's life. In the second half of the 20th century, reconstruction of the ossicular chain so that hearing in the affected ear could be improved after the treatment became an additional, second goal of treatment for chronic otitis media. Simultaneously, great advances were made in the surgical treatment of otosclerosis [3, 7–10].

AIM

The aim of the present study was to establish the possibility of using the chorda tympani as a stabilizing element in the surgical treatment of certain middle ear disorders, such as in the ossicular chain reconstruction in chronic otitis media, as well as in patients operated on for otosclerosis.

MATERIAL AND METHODS

Medical records of patients having received surgical treatment between 2008 and 2018 were taken into account in the analysis. In that period, the chorda tympani was used in 35 different reconstructions of the ossicular chain within the total number of 774 patients operated on at the Department for various middle ear disorders (487 surgeries due to chronic inflammatory lesions, 274 surgeries due to otosclerosis, and 13 surgeries due to other causes). Most patients were in the age group of 41 to 50 years old. Patients operated on for middle ear tumors were subjected to different types of petrosectomies and were excluded from this analysis. Patients with temporal bone injuries were also excluded from the analysis. The patient cohort was divided into 2 independent groups. One group consisted of patients suffering from various forms of chronic otitis media, where reconstructions of the damaged ossicular chain were carried out after the removal of lesions using different materials and/or various prostheses, and the reconstructed chains were stabilized using the chorda tympani. The second group consisted of patients diagnosed with otosclerosis as the only pathology in whom difficulties in stable, permanent fixation of the prosthesis mounted on the long crus on the incus were encountered in the course of the typical surgery, as per the subjective reports of the operators (Fig. 2.).

Prior to the surgery, each patient was subjected to tonal and verbal audiometry and tympanometry with the stapedius muscle assessment. The latter pursued particularly in cases of suspected otosclerosis. Although the abnormalities of the lining of the middle ear space in chronic otitis media were usually advanced, identification of the chorda tympani was quite easy in most of these patients (more than 90%). The continuity of the chorda tympani within the tympanic cavity was disrupted in 53% of those examined for inflammatory conditions of the middle ear, including patients with cholesteatoma, granuloma, or both of these middle ear pathologies.

After the removal of the lesion, appropriate ossicular chain reconstruction was performed depending on the degree of damage to the middle ear structures, using the patient's allogeneic material or designated artificial prostheses, and followed by the reconstruction of the tympanic membrane. Whenever the anatomical conditions allowed, the operating team strove to preserve the chorda tympani during the surgical procedure.

If the chorda tympani was preserved in the course of the inflammatory conditions of the middle ear, a 3D-modeled incus body, prosthesis, cartilage, or other material used in the reconstruction of the ossicular chain to improve hearing could be inserted underneath. The chorda tympani participated in the reconstruction by providing static stabilization to the reconstructed ossicular chain. In some cases, the above reconstruction results in a somewhat worse transmission of vibrations from the tympanic cavity to the foot of the stapedius footplate, especially when the chorda tympani is intact. The transmission of vibration is better if only one end of the chorda tympani can be found in the tympanic cavity; still, the operator should not transect the chorda tympani just for this purpose and has never done so in the presented cases. If only a stump of the chorda tympani was identified in the tympanic cavity, attempts at its mobilization were always made to use this part for reconstruction. The effectiveness of this manipulation was verified intraoperatively by pressing onto the reconstructed ossicular chain and looking for a bulge within the round window membrane. After visualization of bulging and confirmation of structural stability with chorda tympani preventing the structure from any changes in its position (i.e. Stabilizing the structure), this stage of surgery was completed.

Similarly, in the treatment of otosclerosis, the chorda tympani was used in cases of subjective difficulties in placing the prosthesis

onto the second ossicle. In 13 patients operated on for otosclerosis, the operator's assessment was that the prosthesis placed on the long crus of the incus was at risk of dislocation, while any further clamping of the prosthesis on the long crus created the risk of bone necrosis or damage. In these cases, the head of the prosthesis was stabilized by the mobilized chorda tympani being placed onto the prosthesis and the long crus.

After discharge from the clinic, otolaryngological and audiological check-ups were held within the ENT Department's outpatient clinic after 2 weeks, 3 months, and periodically as part of long-term outpatient follow-up.

RESULTS

None of the patients operated on in this way required resurgery, while normal tympanic membrane mobility and improvement of hearing on verbal audiometry relative to the recognition thresholds before surgery were observed in both patients treated for chronic otitis media and those treated for otosclerosis. Similarly, improvements were observed after surgical treatment in all patients on tone audiometry exams compared to the preoperative hearing thresholds. No adhesions were observed between the tympanic membrane and the chorda tympani showing therethrough. Pure tone threshold audiometry tests were pursued in all the patients operated on and subjected to chorda tympani-based stabilization of the reconstructed ossicular chain 3 months after the surgery to show a hearing improvement of 15 to 25 dB within the speech spectrum, depending on the type of the tympanoplasty procedure. In word recognition tests rather than digit recognition tests, the improvement was 10 to 25 dB compared to the respective preoperative recognition thresholds.

DISCUSSION

ENT surgeons may frequently encounter the presence of chorda tympani in the surgical field and the dilemma regarding its potential use in reconstructive surgery [2, 3, 6–8, 10].

The authors propose a solution that they themselves use in their practice with excellent results.

New elements of operational knowledge are being added by the proposal. Whether the reader will take advantage of our suggestion remains a separate question. The establishment of an antithetical control group was impossible, as the ossicular chain structures obtained without the use of chorda tympani would be unstable and likely require resurgery. In our opinion, this would entail acting against the obligation of due diligence while treating the patient and against best will and knowledge. We believe that it was sufficient to verify the success of reconstruction by means of visual confirmation of the bulging of the membrane covering the round window, and therefore, said bulging was used as the intraoperative determinant of complete reconstruction.

When aiming at using the chorda tympani for reconstruction purposes while not causing iatrogenic damage thereto, the operator must first mobilize the index structure using a slightly curved needle or a "battle scythe"-shaped tool following the initial dissection of the tympanic membrane and auditory canal skin flap at the beginning of the procedure [10]. Mobilization should be carried out slowly and carefully, between the first and the second ossicles, as this is the location where the mobilization is most effective and thus facilitates elongating the chorda tympani without the unsought damage. This, however, must be kept in mind from the very beginning of the procedure. There are numerous practical opportunities for the use of the chorda tympani for the improvement of hearing acuity and speech recognition. The advantage of chorda tympani over other tissues that can be used to stabilize ossicular chain structures (e.g., fascia, muscle, fat, blood clots) lies in its lack of scarification potential and low risk of adhesions (which can cause impaired mobility of the new structure) as well as in lower weight of the resulting structure. Based on their studies on chorda tympani in animals, some authors have reported on the structure's participation in the maintenance of normal pressure within the middle ear. The results of our study suggest a possibility of expanding the applicability of the chorda tympani in ear reconstructive surgeries. The optimum solution should be as close as possible to the physiological function of the reconstructed structure, and the simplest actions and handiwork offer the best chance of a good and lasting result. The heavier structures of the new ossicular chains are responsible for the worse results of functional hearing improvement, as well as lead to increased fluid pressure within the inner ear. The latter is sometimes manifested by vertigo and nystagmus, as well as in impaired comprehension of speech. Such heavier structures are encountered more frequently

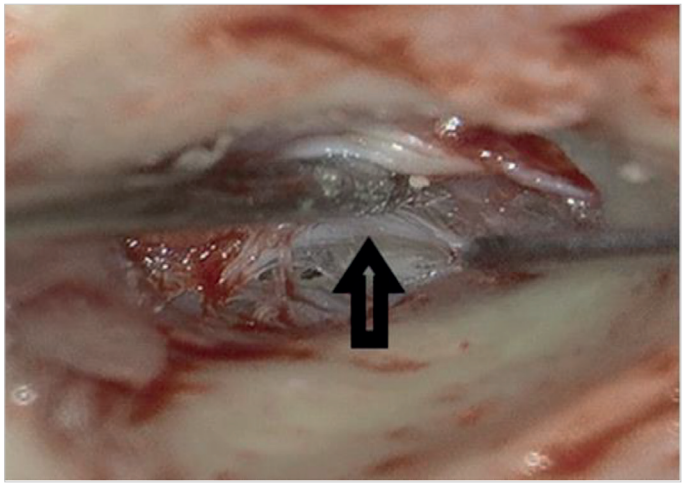

Fig. 1. Intraoperative photograph – the arrow indicates the chorda tympani within the tympanic cavity before its release and mobilization.

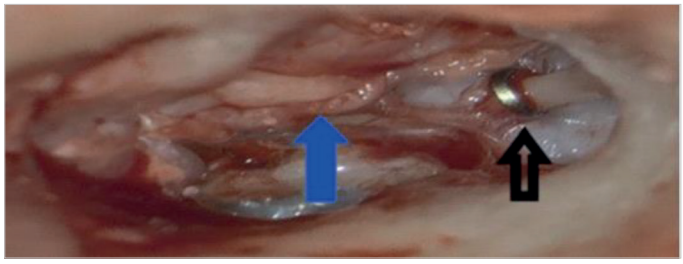

Fig. 2. Dissected and mobilized chorda tympani (blue arrow) for possible positioning of the prosthetic head of the long crus of the incus (black arrow). An intraoperative photograph.

when muscle, cartilage, or fat tissue is used for stabilization. Obviously, the types of reconstruction surgeries aimed at reconstructing new ossicular chains in patients receiving surgeries for chronic otitis media varied among the patients described herein[2, 3, 7, 8, 11–13]. Intraoperative evaluation of the use of the chorda tympani to stabilize the structure of the new ossicular chain or, analogously, during surgery in otosclerosis, was always made by the operator on subjective premises and performed according to his or her best will and knowledge. Statistical surveys were not conducted as they had been deemed unnecessary. The authors suggest that chorda tympani may be likewise used in congenital malformations of the middle ear, as long as it is present and as long as the stapedius footplate remains mobile. However, no such surgeries were ever performed in our facility. Likewise, no prior attempts were made at using the chorda tympani for the stabilization of electronic hearing amplifiers on the incus.

CONCLUSIONS

Chorda tympani can be used intraoperatively to stabilize the reconstructed ossicular chain.

REFERENCES

1. Bull T.R.: Taste and the chorda tympani. J Laryngol Otol., 1965; 79: 479–493. doi: 10.1017/s0022215100063969.
2. Claerhou M., Leupe P.J., Verhaert N., Desloovere C.: Long-term follow-up of chorda tympani function after middle ear surgery. Acta Otorhinolaryngol Belg., 2019; 15: 265–271.
3. Goyal A., Singh P.P., Dash G.: Chorda tympani in chronic inflammatory middle ear disease. Otolaryngol Head Neck Surg., 2009; 140(5): 682–686. doi: 10.1016/j.otohns.2008.12.059.
4. Quancheng L., Jiangatao Z., Liang C.: Variation and protection of the chorda tympani nerw in endoscopic ear surgery. Laryngoscope Investing Otolaryngol., 2022; 7(4): 1107–1112. doi: 10.1002/lio2.838.
5. Rao A., Todi P.: Anatomy Head and Neck, Chorda Tympani. 2023, Mar 4. In Stat Pearls (Internet) Treasure Island (FL): Stat Pearls Publishing 2025.
6. Chawdhary G., Lavy J.: The chorda tympani retractor in stapedectomy. Clin Otolaryngol., 2018; 43: 975–976. doi: 10.1111/coa.12929.
7. Boron A., Wiatr A., Skladzien J., Wiatr M.: The effect of preserved stapedial superstructure on hearing improvement. Otolaryngol Pol., 2020; 74(1): 17–21. doi: 10.5604/01.3001.0013.5954.
8. Sham E.H., Prepageran N., Raman R., Quek K.F.: Chorda tympani nerve function after myringoplasty. Med J Malaysia., 2007; 62(5): 361–363.
9. Niemczyk K.: Tympanoplastyka typu otwartego – wskazania, technika operacyjna. Pol Otorhino Rev., 2012; 1(2): 92–96.
10. Pietruski J.: Operacje tympanoplastyczne. PZWL. Warszawa, 1984.
11. Rinaldi V., Cappadona M., Gaffuri M., Torretta S., Pignataro L.: Chorda tympani nerve, may it have a role in stabilizing middle ear pressure? Med Hypotheses., 2013; 80(6): 726–727. doi: 10.1016/j.mehy.2013.02.021.
12. Wiatr A., Wiatr M.: Unfavourable prognostic factors in patients treated surgically for otosclerosis. Acta Otolaryngol., 2020; 140(7): 533–536. doi: 10.1080/00016489.2020.1745270.
13. Wiatr M., Składzień J., Tomik J.: Przewlekłe zapalenie ucha środkowego jako wstęp do usznopochodnych powikłań wewnątrzczaszkowych. Otolaryngol Pol., 2008; 62(1): 49–53.

Table of content: https://otorhinolaryngologypl.com/issue/17010 Tables: – Figures: 2 References: 13

Copyright: Some rights reserved: Polish Society of Otorhinolaryngologists Head and Neck Surgeons. Published by Index Copernicus Sp. z o.o.

Competing interests: The authors declare that they have no competing interests.

The content of the journal „Polish Society of Otorhinolaryngologists Head and Neck Surgeons" is circulated on the basis of the Open Access which means free and limitless access to scientific data.

This material is available under the Creative Commons – Attribution-NonCommercial 4.0 International (CC BY-NC 4.0). The full terms of this license are available on: https://creativecommons.org/licenses/by-nc/4.0/legalcode

Corresponding author: Jacek Składzień (0000-00003-4778-1281); Jagiellonian University Medical College; Kraków, Poland; E-mail: skladzien.j@interia.pl

Cite this article as: Ziarno R., Sobus M., Grudzien-Ziarno A., Wiatr M., Wiatr A., Kocon S. et al.: Chorda tympani and its potential for the stabilization of the ossicular chain as based on the experience of the Department of Otolaryngology at the University Hospital in Kraków, Poland; Pol Otorhino Rev 2025; 14 (4): 26–29;DOI: 10.5604/01.3001.0055.5022