INDEX COPERNICUS INTERNATIONAL

CASE STUDY

A rare case of Madelung's disease in a 65-year-old patient

Rzadki przypadek choroby Madelunga u 65-letniego pacjenta

Authors' Contribution:
A – Study Design
B – Data Collection
C – Statistical Analysis
D – Data Interpretation
E – Manuscript Preparation
F – Literature Search
G – Funds Collection

Jarosław Markowski[1ABDF], Wojciech Smółka[1ABDF], Marta Łopyta-Mirocha[1ABCDEF], Olga Leśniewska-Skowerska[1F], Leon Smółka[2DF]

[1]Department of Laryngology, Silesian Medical University in Katowice, Poland
[2]Students' Scientific Group at the Department of Laryngology, Silesian Medical University in Katowice, Poland

Article history: Received: 20.07.2025 Accepted: 25.11.2025 Published: 26.11.2025

ABSTRACT:

Introduction: Madelung's disease is a rare condition characterized by the presence of numerous symmetrical, painless, non-encapsulated lipomatous masses located in the neck, head, upper limbs, and upper body.

Case report: This paper presents the case of a 65-year-old Caucasian male who was admitted to the Department of Otolaryngology due to symmetrical neck masses and a tumor in the left parotid gland. The patient's medical history revealed chronic alcoholism for approximately 30 years, accompanied by alcoholic liver cirrhosis. Imaging studies and fine-needle aspiration biopsy were performed. Surgical treatment included removal of the tumor from the left parotid gland and bilateral subtotal reduction of the neck masses. The postoperative period was complicated by the formation of a hematoma in the suprahyoid region. The patient is currently under regular follow-up at the ENT outpatient clinic.

Conclusions: Madelung's disease is a rare condition with an unclear etiopathogenesis. This case illustrates a therapeutic approach involving surgical resection of the lesions. Due to the high risk of recurrence, patients who undergo surgical treatment should remain under continuous medical supervision..

KEYWORDS: benign symmetric lipomatosis, Launois-Bensaude syndrome, lipoma, Madelung disease, multiple symmetric lipomatosis

STRESZCZENIE:

Wprowadzenie: Choroba Madelunga to rzadka jednostka chorobowa charakteryzująca się występowaniem w obrębie szyi, głowy, kończyn górnych oraz górnej części ciała symetrycznych, niebolesnych, nieotorebkowanych licznych mas tłuszczaków.

Opis przypadku: W pracy przedstawiono przypadek 65-letniego mężczyzny rasy kaukaskiej, który zgłosił się do kliniki otorynolaryngologii z powodu symetrycznych guzów w obrębie szyi oraz guza ślinianki przyusznej lewej. W badaniu podmiotowym ustalono alkoholizm od około 30 lat z alkoholową marskością wątroby. U chorego wykonano pomocnicze badania obrazowe oraz biopsję aspiracją cienkoigłową. Przeprowadzono zabieg chirurgiczny mający na celu usunięcie guza śliniaki przyusznej lewej oraz obustronną subtotalną redukcję masy guzów w obrębie szyi. Okres pooperacyjny był powikłany wystąpieniem krwiaka okolicy nadgnykowej. Aktualnie pacjent przebywa pod stałą, regularną kontrolą w poradni laryngologicznej.

Wnioski: Choroba Madelunga to rzadka jednostka chorobowa o niejasnej etiopatogenezie. Na podstawie opisanego przypadku przedstawiono przykładowe postępowanie terapeutyczne, polegające na chirurgicznej resekcji zmian. Ze względu na duże ryzyko nawrotu pacjenci po leczeniu chirurgicznym powinni pozostać pod stałą kontrolą.

SŁOWA KLUCZOWE: choroba Madelunga, łagodna symetryczna tłuszczakowatość, mnoga symetryczna tłuszczakowatość, tłuszczak, zespół Launoisa-Bensaude'a

ABBREVIATIONS

BSL – benign symmetric lipomatosis
FNAB – fine needle aspiration biopsy
MSL – multiple symmetric lipomatosis

INTRODUCTION

Madelung's disease, also referred to as multiple symmetric lipomatosis (MSL), Launois-Bensaude syndrome, or benign symmetric lipomatosis (BSL) is a rare condition characterized by the



Fig. 1. Patient with Madelung's disease upon admission before surgery; (A) front view; (B) back view; (C) left-side view; (D) right-side view.

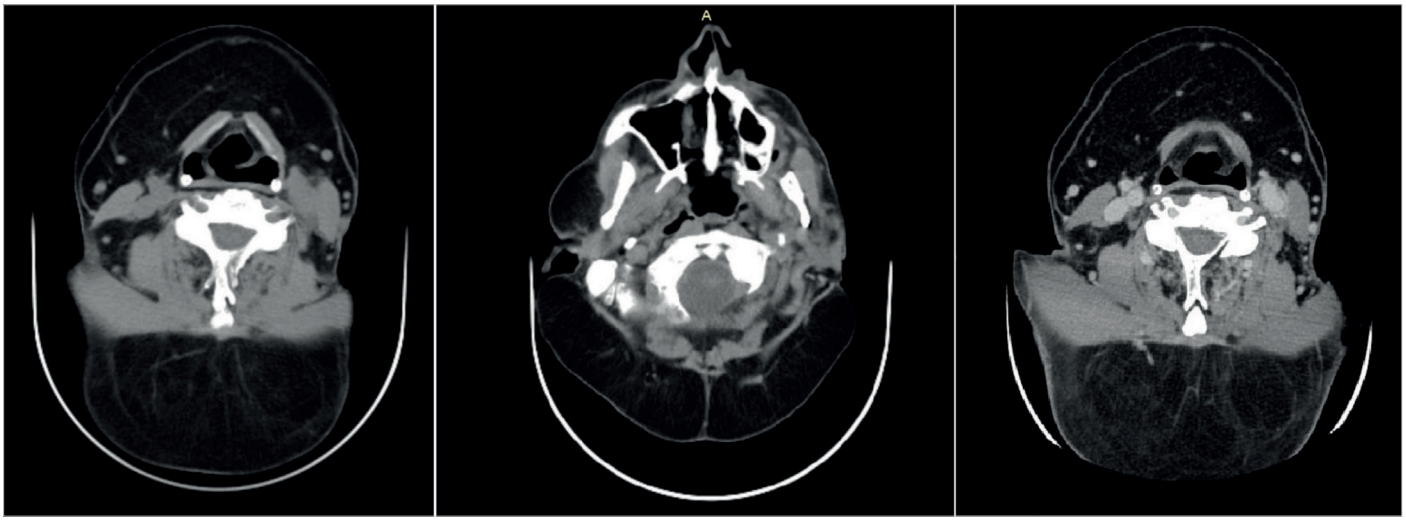

Fig. 2. Pre-treatment CT scan.

presence of numerous symmetrical, painless, non-encapsulated lipomatous masses located in the neck, head, upper limbs, and upper body [1–3].

The disease mainly affects men, usually between 30 and 60 years of age [1, 4–6]. The prevalence rate of Madelung's disease is 1:25,000 [7]; the etiology remains unclear. The condition is most common in the Mediterranean population of Caucasians [1, 2]. A correlation with alcohol abuse has been found, with more than 90% of patients presenting with alcohol use disorder [2, 3, 8]. Common comorbidities include polyneuropathy, diabetes, nephropathy, cirrhosis, hyperuricemia, macrocytic anemia, hypothyroidism, and malignancies [1, 3, 6, 8].

The disease can take a rapid course, or the lesions can grow slowly and symmetrically over the years. Due to their mass, disease-related fat deposits can cause a number of symptoms, such as shortness of breath, dysphagia, and headaches, as well as restrict the mobility of the neck [7]. Hoarseness, dry cough, facial flushing, reduced mobility, gastrointestinal distress, excessive sweating, and increased salivation upon eating are also commonly reported [3]. In most cases, the course of the disease is slow, and cases of malignant transformation are very rare [8].

CASE REPORT

A 65-year-old patient was admitted on an elective basis to the Department of Otorhinolaryngology due to symmetrical tumors within the neck as well as a tumor of the left parotid gland (Fig. 1.). Upon admission, the patient was in good general condition, denying

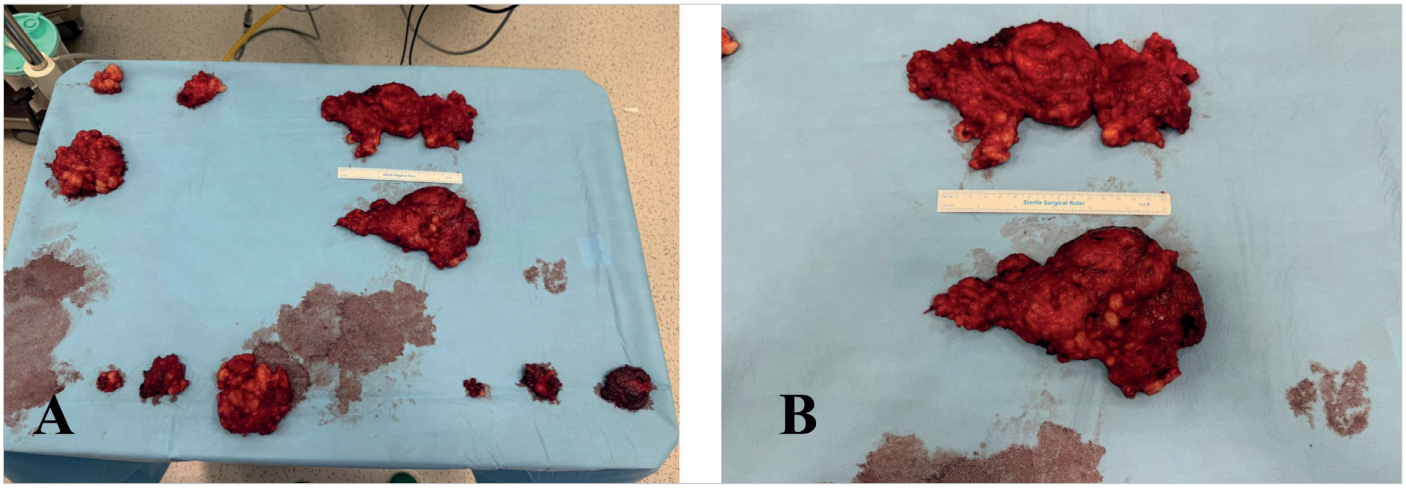

Fig. 3. Removed lipomatous masses.



Fig. 4. Patient on day 6 after the surgery; (A) right-side view; (B) front view; (C) left-side view.

any symptoms of shortness of breath, pain, or hearing loss. Medical history revealed that the neck tumors had developed about 13 years before presentation; the lesions were initially small, and continued to grow in a symmetric and gradual fashion. In addition, a tumor was found in the left parotid gland along with persistent hoarseness over the past 3 months. The patient denied any general symptoms such as weight loss, elevated body temperature, or night sweats.

History: alcoholic liver disease, history of alcohol abuse for about 30 years, has not been drinking for 3 months. History of appendectomy about 25 years prior to presentation; no other disease burden. Physical examination revealed similar-looking lesions on the upper torso and the upper extremities. Other findings included left vocal fold paresis and a wide glottis of good respiratory capacity. Deviations in laboratory tests as of the day of admission: WBC $10.27 \times 10^3/\mu L$, PLT $741 \times 10^3/\mu L$. Body mass index 26.87 kg/m^2.

A CT scan of the neck and chest revealed (Fig. 2.): fatty transformation of both parotid glands – suspicion of chronic sialadenitis. Heterogeneous, asymmetric submandibular salivary glands – smaller on the right side, with no overt proliferative lesions or dilatation of salivary ducts. No tissue lesions at the level of the larynx. Suspicion of Klippel–Feil syndrome with C3-C4 coalition. Atherosclerotic arteries. No proliferative lesion potentially explaining the paralysis of the recurrent laryngeal nerve found at the left hilum level. Two micronodular tumor lesions up to 5 mm in diameter at the level of the apical segment of the right lower lung lobe – probably granulomas. Lingering Forestier's disease.

Fine needle aspiration biopsy (FNAB) of the neck tumor on the left side: "Diagnostic smear test. Cancer cells present. *Tumor mixtus* to be differentiated from cancer. Histopathological examination indicated."

After follow-up laboratory tests and additional consultations, the patient was qualified for surgery under general anesthesia.

Left parotidectomy was performed at levels I–IV with preservation of the facial nerve and the resection of the left submandibular salivary gland in hyperplastic fat. Fatty tumors on the lateral left side of the neck were dissected and partially removed up to the



Fig. 5. Patient at 5 months after the surgery. Facial nerve function preserved, symmetrical.

nape area. An analogous procedure was performed on the right side, including right parotidectomy at levels I-II and reducing the lipomatous masses in the submental region.

Profuse bleeding was encountered intraoperatively. Skin plasty was performed to remove excess skin.

About 3,500 g of fatty lesions were removed (Fig. 3.). On the first day after surgery, the wound was revised, and numerous blood clots were removed from the suprahyoid area. The origin of the bleeding could not be identified. Temporary tracheotomy was performed to secure airway patency.

On postoperative day 6, the drain was removed, the patient was decannulated, and the tracheotomy was sutured (Fig. 4.). On postoperative day 7, the patient was discharged home in good general and local condition. Histopathological examination revealed salivary gland parenchyma presenting with features of fat atrophy, adipose tissue unremarkable upon microscopic examination, and 5 lipomas with the diameters of 13 cm, 9 cm, 15 cm, 10 cm, and 6.5 cm, respectively. No neoplastic lesions were found.

The patient remains under regular care of the outpatient otorhinolaryngology clinic. Fig. 5. shows the local condition of the patient 5 months after the surgery.

DISCUSSION

The first description of benign symmetric lipomatosis was provided by Benjamin Brodie in 1846 [8]. A series of 35 patients was described in 1888 by Otto W. Madelung. In 1898, P.E. Launois and R. Bensaude described the disease on the basis of 65 of their patients [1, 3, 6]. To date, about 600 cases have been reported worldwide [9].

Madelung's disease mainly affects men (M:F – 15:1) in the middle-aged range. Correlation with a history of alcoholism has been established in most cases [3, 7, 9]. However, literature contains reports on non-drinkers being affected [10, 11]. The condition most frequently affects Caucasian patients, mainly European residents of the Mediterranean region. Rare cases of Asian patients have also been described in the literature [1, 3].

The etiopathogenesis of Madelung's disease is unknown [1, 7]. Hypotheses are suggestive of a mutation in mitochondrial DNA, disruption of adrenergic stimulation of lipolysis, and structural changes within adipocyte membrane receptors [1, 8]. These changes are related to an increase in the number of fat cells, rather than hypertrophy. Lipomatous masses are better vascularized compared to unilocular lesions; they are non-encapsulated and have a cherry red color [3, 6].

As of the present, two main classifications of Madelung's disease have been proposed. The first one, proposed by G. Enzi in 1984, distinguishes between two types of the disease based on the clinical presentation. Type I is characterized by symmetrical superficial distribution of fatty masses, mainly within the nape, shoulders, and neck in the form of a characteristic "Madelung's collar" or "horse collar". Patients (mostly men) present a "pseudo-athletic" appearance. The clinical presentation of type II is similar to that of generalized obesity, with lipomas accumulating mainly in the abdomen and thighs. The disorder affects both men and women [1, 7, 12]. The second classification system, developed by G. Donhauser in 1991, distinguishes between three types of accumulation patterns: type I (horse collar), type II (pseudo-athletic), and type III (gynoid) [13]. Importantly, no particular subtype has any effect on prognosis or the choice of management [6].

The diagnosis is made on the basis of clinical features and supportive imaging studies [1, 5, 7]. Macrocytic anemia is the most common abnormal finding in basic laboratory tests. Otherwise, no deviations from the normal ranges are observed in most cases. Literature reports are available on the cases of Madelung's disease in both normal-weight patients and patients with elevated BMI values [3].

The differential diagnosis should include simple obesity, steroid obesity, Cushing's syndrome, encapsulated fibromas, neurofibromatosis, angiolipomatosis, adiposogenital dystrophy,

neck cysts, thyroid cancer, liposarcomas, fibromas, lymphomas, and salivary gland diseases [3, 6, 13].

The treatment of multiple symmetrical lipomatosis is difficult and frequently fails at yielding satisfactory results. The treatment approach can be divided into surgical and non-surgical methods. The most common method of treatment is surgical removal of lipomatous deposits. The lesions tend to recur, and patients require multiple resections, which frequently fail to lead to long-term results [1, 3, 6]. In most cases, safe and radical removal of all lesions is not possible [3]. Some authors suggest that the resection of lipomas should be considered only after cessation of drinking due to the risk of accelerated recurrence [10].

Other treatment options include liposuction and injection lipolysis [1, 5, 7]. Dietary treatment is ineffective in most cases [3, 7, 8].

CONCLUSIONS

Madelung's disease is a rare metabolic condition entity with an incompletely elucidated etiopathogenesis and about 600 cases described so far. Surgical resection of the lesions has been illustrated on the basis of the presented case. As of the present, resection is the most common treatment method, facilitating more radical elimination of lesions. Due to the high risk of recurrence, patients should remain under constant observation.

REFERENCES

1. Młodkowska A., Kopeć T., Leszczyńska M.: Benign multiple symmetrical lipomatosis – a case report of patient with Madelung's disease. Adv Head Neck Surg., 2010; 9(2): 30–34.
2. Chen K.K., Ni L.S., Yu W.H.: Madelung disease: A case report. World J Clin Cases., 2021; 9(8): 1983–1988. doi: 10.12998/wjcc.v9.i8.1983.
3. Waniczek D., Kamińska E., Kamiński T., Pilch J.: Łagodna symetryczna tłuszczakowatość – choroba metaboliczna o nieznanej etiologii. Ann Acad Med Siles., 2012; 66(6): 85–90.
4. González-García R., Rodríguez-Campo F.J., Sastre-Pérez J., Muñoz-Guerra M.F.: Benign Symmetric Lipomatosis (Madelung's Disease): Case Reports and Current Management. Aesth Plast Surg., 2004; 28(2): 108–113. doi: 10.1007/s00266-004-3123-5.
5. Frąk W., Gocel O., Sieniawski K., Sieniawska J., Włodarczyk M. et al.: Multiple symmetrical lipomatosis: A literature review and case report of a patient with Madelung's disease. Pol Przegl Chir., 2024; 96(Suppl 1): 130–134. doi: 10.5604/01.3001.0053.5997.
6. Musialik K., Bogdański P., Nawrocka M.: Choroba Madelunga – opis przypadku i przegląd piśmiennictwa. Forum Zaburzeń Metabolicznych., 2012; 3(4): 154–159.
7. Jaźwiec P., Pawłowska M., Czerwińska K., Poręba M., Gać P. et al.: Madelung's Disease as an Example of a Metabolic Disease Associated with Alcohol Abuse – Diagnostic Importance of Computed Tomography. Int J Environ Res Public Health., 2022; 19(9): 5168. doi: 10.3390/ijerph19095168.
8. Chen C.Y., Fang Q.Q., Wang X.F., Zhang M.X., Zhao W.Y. et al.: Madelung's Disease: Lipectomy or Liposuction? Biomed Res Int., 2018; 2018: 3975974. doi: 10.1155/2018/3975974.
9. Jiao C., Liu W., Qiao Y., Qi S., Shen Y.: A case report on Madelung's disease and comprehensive review of the literature. Orphanet J Rare Dis., 2024; 19(1): 302. doi: 10.1186/s13023-024-03303-w.
10. El Ouahabi H., Doubi S., Lahlou K., Boujraf S., Ajdi F.: Launois-bensaude syndrome: A benign symmetric lipomatosis without alcohol association. Ann Afr Med., 2017; 16(1): 33–34. doi: 10.4103/1596-3519.202082.
11. Bergler-Czop B., Wcisło-Dziadecka D., Brzezińska-Wcisło L.: Madelung's disease in a patient with chronic renal insufficiency: a case report and review of literature. Postepy Dermatol Alergol., 2014; 31(2): 121–124. doi: 10.5114/pdia.2014.40922.
12. Schiltz D., Anker A., Ortner Ch., Tschernitz S., Koller M. et al.: Multiple Symmetric Lipomatosis: New Classification System Based on the Largest German Patient Cohort. Plast Reconstr Surg Glob Open., 2018; 6(4): e1722. doi: 10.1097/GOX.0000000000001722
13. Maximiano L.F., Gaspar M.T., Nakahira E.S.: Madelung disease (multiple symmetric lipomatosis). Autops Case Rep., 2018; 8(3): e2018030. doi: 10.4322/acr.2018.030.

Table of content: https://otorhinolaryngologypl.com/issue/17010 Tables: – Figures: 5 References: 13

Copyright: Some rights reserved: Polish Society of Otorhinolaryngologists Head and Neck Surgeons. Published by Index Copernicus Sp. z o.o.

Competing interests: The authors declare that they have no competing interests.

The content of the journal „Polish Society of Otorhinolaryngologists Head and Neck Surgeons" is circulated on the basis of the Open Access which means free and limitless access to scientific data.

This material is available under the Creative Commons – Attribution-NonCommercial 4.0 International (CC BY-NC 4.0). The full terms of this license are available on: https://creativecommons.org/licenses/by-nc/4.0/legalcode

Corresponding author: Marta Łopyta-Mirocha; Department of Laryngology, Silesian Medical University in Katowice; Katowice, Poland; E-mail: marta.lopyta@gmail.com

Cite this article as: Markowki J., Smolka W., Lopyta-Mirocha M., Lesniewska-Skowerska O., Smolka L.: A rare case of Madelung's disease in a 65-year-old patient; Pol Otorhino Rev 2025; 14 (4): 1–5; DOI: 10.5604/01.3001.0055.4580