INDEX COPERNICUS INTERNATIONAL

CASE STUDY

Penetrating neck injury. A case report

Uraz penetrujący szyi. Opis przypadku

Authors' Contribution:
A – Study Design
B – Data Collection
C – Statistical Analysis
D – Data Interpretation
E – Manuscript Preparation
F – Literature Search
G – Funds Collection

Wiktor Antoni Niemczyk[1ABCDEF], Aleksandra Garbacik[1ABCDEF], Daniel Majszyk[2ABCDEF], Antoni Bruzgielewicz[2ABCDEFG]

[1]Medical University of Warsaw, Poland
[2]Department and Clinic of Otorhinolaryngology, Head and Neck Surgery, Medical University of Warsaw, Poland

Article history: Received: 16.10.2025 Accepted: 07.12.2025 Published: 08.12.2025

ABSTRACT:

Introduction: Penetrating neck injuries (PNIs) are rare yet potentially life-threatening events accounting for 5–10% of all trauma cases. Due to the complex anatomy of the neck area, even small wounds can result in damage to key structures such as large blood vessels, airways, or nerves. Proper management requires prompt assessment in accordance with Advanced Trauma Life Support (ATLS) principles, stabilization of vital functions, and immediate surgical intervention.

Case report: A 24-year-old woman with a history of depressive disorders, at two months postpartum, was found with a knife penetrating the anterolateral part of her neck. At the time of the emergency team's arrival, the patient was conscious, circulatorily and respiratorily stable. Following the securing of airways and intubation, she was transported by helicopter to a reference center. A CT scan showed the knife blade penetrating through the soft tissues of the neck on the left side, its tip within the C6 vertebral body, with no signs of damage to large vessels. Urgent surgical exploration was performed to reveal no damage to the carotid vessels, larynx, or esophagus. The knife was removed from the vertebral body, and the minor osseous bleeding was managed by a neurosurgeon. In the post-operative period, the patient experienced transient limb paresis, which completely resolved after rehabilitation.

Conclusions: Penetrating neck injuries require immediate diagnosis and interdisciplinary management. It is crucial that the patient be transported to the medical facility with the impaled instrument in place, with no attempts having been made at removing it, and that prompt imaging and surgical evaluation be pursued upon presentation. Surgical management should include thorough exploration and hemostasis control by specialist teams. The presented case illustrates the diagnostic and therapeutic procedures that need to be pursued in case of a PNI.

KEYWORDS: cervical spine, depressive disorders, penetrating neck injury, trauma surgery

STRESZCZENIE:

Wstęp: Urazy penetrujące szyi należą do rzadkich, lecz potencjalnie zagrażających życiu obrażeń, co stanowi 5–10% wszystkich urazów. Ze względu na złożoną anatomię tej okolicy nawet niewielkie rany mogą prowadzić do uszkodzenia kluczowych struktur, takich jak: duże naczynia krwionośne, drogi oddechowe czy nerwy. Właściwe postępowanie wymaga szybkiej oceny zgodnej z zasadami Advanced Trauma Life Support (ATLS), stabilizacji funkcji życiowych oraz niezwłocznej interwencji chirurgicznej.

Opis przypadku: 24-letnia kobieta z rozpoznanymi zaburzeniami depresyjnymi, 2 miesiące po porodzie, została znaleziona z wbitym nożem w przednio-boczną część szyi. W chwili przyjazdu zespołu ratunkowego była przytomna, stabilna krążeniowo i oddechowo. Po zabezpieczeniu dróg oddechowych i intubacji została przetransportowana śmigłowcem do ośrodka referencyjnego. W badaniu tomografii komputerowej uwidoczniono ostrze noża przebiegające przez tkanki miękkie szyi po stronie lewej, z końcem w trzonie kręgu C6, bez cech uszkodzenia dużych naczyń. W trybie pilnym wykonano eksplorację chirurgiczną i nie stwierdzono uszkodzeń naczyń szyjnych, krtani ani przełyku. Neurochirurg usunął nóż z trzonu kręgu i zaopatrzył niewielkie krwawienie kostne. W okresie pooperacyjnym wystąpił przemijający niedowład kończyn, który całkowicie ustąpił po rehabilitacji.

Wnioski: Urazy penetrujące szyi wymagają natychmiastowej diagnostyki i interdyscyplinarnego postępowania. Kluczowe znaczenie ma transport pacjenta z wbitym narzędziem bez jego usuwania, a także szybka ocena obrazowa i chirurgiczna. Postępowanie operacyjne powinno obejmować dokładną eksplorację i kontrolę hemostazy z udziałem zespołów specjalistycznych. Przedstawiony przypadek pokazuje, jakie procedury diagnostyczno-terapeutyczne winny być wdrożone.

SŁOWA KLUCZOWE: chirurgia urazowa, kręgosłup szyjny, uraz penetrujący szyi, zaburzenia depresyjne

WYKAZ SKRÓTÓW

ATLS – Advanced Trauma Life Support
CT – computed tomography
GCS – Glasgow Coma Scale
PNI – Penetrating neck injury

INTRODUCTION

Penetrating neck injury (PNI) is defined as trauma resulting in damage to the platysma muscle and the structures located underneath [1]. The neck region contains numerous anatomical structures located in close proximity to one another and presenting with the potential of being damaged as a result of a PNI. Penetrating injuries to the neck account for 5–10% of all traumatic events [2], their mortality rate amounting up to 10% [3]. Most frequently, they are the result of stab wounds, followed by gunshot wounds [4]. Structures subject to damage in penetrating neck injuries include, in the order of decreasing frequency, the internal jugular vein, the cervical spine, the larynx, the external jugular vein, the vertebral arteries, the esophagus, and the vagus nerve [5]. All PNIs should be considered potentially life-threatening and requiring urgent intervention due to possible damage to structures such as large blood vessels, airways, and/or nerves. The immediate management requires clearing the airway, ensuring ventilation, and preventing circulatory decompensation, followed by a detailed assessment of the injury and proper surgical wound care. This procedure minimizes the likelihood of severe complications.

CASE REPORT

A 24-year-old woman with a history of recurrent depressive disorders, at 2 months postpartum, was found by her husband with a knife penetrating into the anterolateral part of her neck (Fig. 1.).

As assessed by the paramedics at the scene, the patient was conscious, Glasgow Coma Scale (GCS) 15, circulatorily and respiratorily stable, and mildly agitated. The patient was administered pharmacological sedation, intubated, and transported by helicopter to the hospital.

A computed tomography (CT) scan was performed at the hospital. According to the radiologist's report, the examination revealed a knife penetrating the soft tissues of the neck on the left side at the level of the thyroid cartilage. The tip of the knife had most likely penetrated into the spinal canal at the C6 level (Fig. 2.).

Air can be seen within the soft tissues of the neck and medially at the pharyngeal level, possibly suggesting damage to the larynx or esophagus. Small infiltrates and fluid spaces suggestive of hematoma are visible on the left side along the pharynx and larynx. No signs of overt contrast leakage from the blood vessels; due to the limited scope of possible evaluation, damage to the branches of the carotid artery on the left side could not be excluded.

The patient was operated on urgently. The trauma wound was widened along the extension of the long axis. Large blood vessels such as the common carotid artery and the internal jugular vein were dissected. The throat and the larynx were isolated and moved towards the midline. No damage to any of the above structures was observed upon intraoperative exploration (Fig. 3.).

Next, deeper tissues were dissected, reaching the prevertebral fascia. The tip of the knife was located within the C6 cervical vertebral body. A neurosurgeon called in to assist in the operation removed the knife from the vertebral body and stopped the bleeding from the wound that had formed therewithin (Fig. 4.). Thorough hemostasis was achieved, the wound was closed in layers, and a sterile dressing was applied.

After being transported to the recovery room, the patient remained conscious, in verbal logical contact, circulatorily and respiratorily stable, and capable of moving all limbs. On the next day, slight limb paresis was noticed, and a neurology consultation was pursued. Neurological examination revealed mild paresis within the left lower limb and the upper limbs, Lovett scale 4 (patient able to counter the resistance from the examiner). The patient was referred to the neurology department for further rehabilitation. After a month of rehabilitation, the patient's paresis resolved completely. The patient was referred for outpatient treatment of depressive disorder.

DISCUSSION

The neck is bounded superiorly by the inferior border of the mandible and inferiorly by the superior surface of the sternum, clavicle, and acromion [6]. The neck can be divided into anterior, lateral, and sternocleidomastoid regions and neck triangles. This division is important for the identification of key anatomical structures. Historically, the management of penetrating neck injuries were determined by the injury being located in either of the 3 zones [7], namely zone I extending from the clavicles and suprasternal notch to the annular cartilage, zone II between the annular cartilage and the angle of the mandible, and zone III between the angle of the mandible and the base of the skull [8]. The zone dogma has recently been questioned, particularly as the external location of wounds is poorly correlated with the exact extent of damage to deeper tissues. For this reason, a 'no zone' approach has been proposed [9]. Patients with penetrating neck injuries can fall into shock due to blood loss at any time and should be transported to the hospital immediately. The impaled objects should only be removed in the hospital under the settings of the operating room. The preliminary assessment is pursued as per the Advanced Trauma Life Support (ATLS) principles [10]. The airways need to be supplied immediately, with the initial assessment of damage to the mouth, pharynx, larynx, and trachea being done as soon as possible [11]. The bleeding can be temporarily stopped by tamponade using a Foley catheter inserted directly into the wound, before the source of bleeding is identified and an endovascular or surgical intervention follows [12]. If vascular damage to the neck is confirmed, a vascular surgeon should be consulted immediately. If possible, damage to the common or internal carotid artery should be addressed by direct suturing of the edges instead of ligation, as this reduces the incidence of complications such as stroke [13]. The management of vertebral artery damage can be challenging due to the vessel's location. In circulatorily unstable patients or in cases when bleeding could not be stopped by endovascular intervention,



Fig. 1. A knife penetrating into the anterolateral part of the neck.

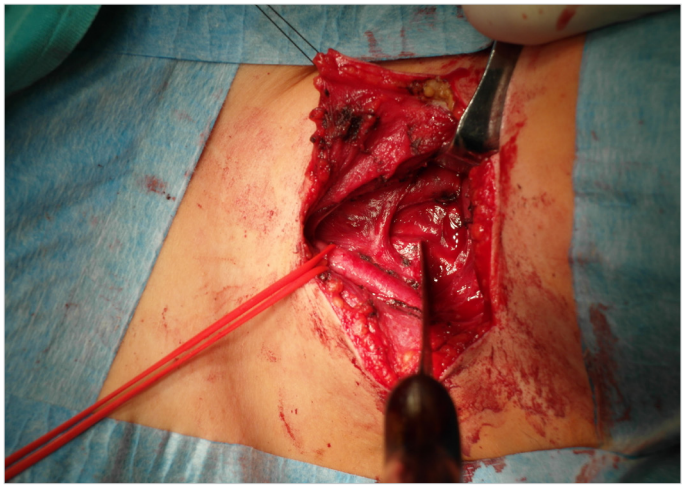

Fig. 3. The surgical field with the knife in place.

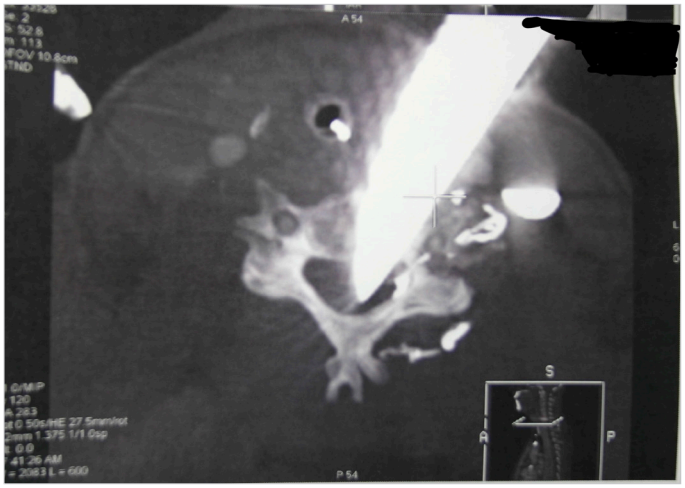

Fig. 2. CT scan – the tip of the knife penetrating into the C6 vertebral body.

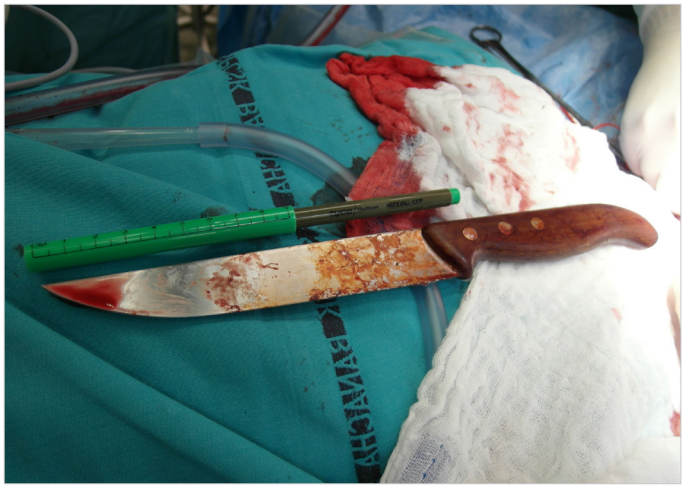

Fig. 4. The removed knife.

the bleeding vessels can be ligated [14]. Ligation of the damaged venous vessels is usually possible due to the highly developed network of collateral vessels [15]. In cases of bilateral damage to the internal jugular veins, primary repair of the vessels should be attempted [16]. While minor injuries to the esophagus and trachea can be managed by primary suturing following the removal of tissue until a healthy margin, more than 50% of injuries to these structures require segmental excision and reconstruction [17]. Due to the large number of key structures within the neck, PNIs can lead to numerous complications and permanent disability for patients. Possible complications include brachial and cervical plexus damage, dysphagia, vocal cord paralysis, and dyspnea requiring tracheotomy [18]. Thorough physical examination and radiological diagnostics facilitate appropriate planning of the surgery, which increases the safety of the procedure and can reduce the incidence of complications [19].

In the case reported herein, there was no damage to the main arterial or venous vessels of the neck, as well as to the airways and esophagus. The paresis within the limbs was of low severity and subsided over time, eventually resolving completely. Considering the mechanism, the tool, and the site of the injury, the encountered complications were minimal.

CONCLUSIONS

Several surgical teams are usually involved in the treatment of multi-organ trauma; in the case described herein, an ENT surgeon required the assistance of a neurosurgery specialist. Prompt intervention and coordination between teams is the key to successful management of PNIs.

REFERENCES

1. Puttamadaiah G.M., Arabhanvi R., Viswanatha B., Menon P.A., Prabhu R.M.: Penetrating Neck Injuries: A Comprehensive Study. Indian J Otolaryngol Head Neck Surg., 2022; 74(Suppl 3): 6189–6194.
2. Vishwanatha B., Sagayaraj A., Huddar S.G., Kumar P., Datta R.K.: Penetrating neck injuries. Indian J Otolaryngol Head Neck Surg., 2007; 59(3): 221–224.
3. Saito N., Hito R., Burke P.A., Sakai O.: Imaging of Penetrating Injuries of the Head and Neck:Current Practice at a Level I Trauma Center in the United States. Keio J Med., 2014; 63(2): 23–33.
4. Burgess C.A., Dale O.T., Almeyda R., Corbridge R.J.: An evidence based review of the assessment and management of penetrating neck trauma. Clin Otolaryngol., 2012; 37(1): 44–52.

5. Blitzer D.N., Ottochian M., O'Connor J., Feliciano D.V., Morrison J.J. et al.: Penetrating Injury to the Carotid Artery: Characterizing Presentation and Outcomes from the National Trauma Data Bank. Ann Vasc Surg., 2020; 67: 192–199.
6. Kohan E.J., Wirth G.A.: Anatomy of the Neck. Clin Plast Surg., 2014; 41(1): 1–6.
7. Low G.M.I., Inaba K., Chouliaras K., Branco B., Lam L. et al.: The Use of the Anatomic 'Zones' of the Neck in the Assessment of Penetrating Neck Injury. Am Surg., 2014; 80(10): 970–974.
8. Roon A.J., Christensen N.: Evaluation and Treatment of Penetrating Cervical Injuries. J Trauma Acute Care Surg., 1979; 19(6): 391.
9. Nowicki J., Stew B., Ooi E.: Penetrating neck injuries: a guide to evaluation and management. Ann R Coll Surg Engl., 2018; 100(1): 6–11.
10. Roepke C., Benjamin E., Jhun P., Herbert M.: Penetrating Neck Injury: What's In and What's Out? Ann Emerg Med., 2016; 67(5): 578–580.
11. Osborn T.M., Bell R.B., Qaisi W., Long W.B.: Computed Tomographic Angiography as an Aid to Clinical Decision Making in the Selective Management of Penetrating Injuries to the Neck: A Reduction in the Need for Operative Exploration. J Trauma Acute Care Surg., 2008; 64(6): 1466.
12. Scriba M.F., Navsaria P.H., Nicol A.J., Edu S., Sayari A.A.: Foley-catheter balloon tamponade (FCBT) for penetrating neck injuries (PNI) at Groote Schuur Hospital: an update. S Afr J Surg., 2017; 55(2): 66–67.
13. Feliciano D.V.: Management of penetrating injuries to carotid artery. World J Surg., 2001; 25(8): 1028–1035.
14. Schellenberg M., Owattanapanich N., Cowan S., Strickland M., Lewis M. et al.: Penetrating injuries to the vertebral artery: interventions and outcomes from US Trauma Centers. Eur J Trauma Emerg Surg., 2022; 48(1): 481–488.
15. Farrell M.S., Knudson M.M., Stein D.M.: Venous ligation versus venous repair: does the procedure impact venous thromboembolism risk? Trauma Surg Acute Care Open. 2021; 6(1): e000687.
16. Loss L., Henry R., White A., Matsushima K., Barrett C. et al.: Penetrating neck trauma: a comprehensive review. Trauma Surg Acute Care Open. 2025; 10(1): e001619.
17. Schweiger T., Evermann M., Roesner I., Frick A.-E., Denk-Linnert D.-M. et al.: Laryngotracheal resection can be performed safely without a guardian Chin stitch—a single-centre experience including 165 consecutive patients. Eur J Cardiothorac Surg., 2021; 60(2): 402–408.
18. Al-Thani H., El-Menyar A., Mathew S., Khawar M., Asim M. et al.: Patterns and outcomes of traumatic neck injuries: A population-based observational study. J Emerg Trauma Shock., 2015; 8(3): 154.
19. Marków M., Zieliński M., Kawecka I., Lampe N., Ścierski W.: Urazy drążące szyi. Pol Otorhino Rev., 2017; 6(4): 61–64. doi: 10.5604/01.3001.0010.7506.

Table of content: https://otorhinolaryngologypl.com/issue/17010 Tables: – Figures: 4 References: 19

Copyright: Some rights reserved: Polish Society of Otorhinolaryngologists Head and Neck Surgeons. Published by Index Copernicus Sp. z o.o.

Competing interests: The authors declare that they have no competing interests.

The content of the journal „Polish Society of Otorhinolaryngologists Head and Neck Surgeons" is circulated on the basis of the Open Access which means free and limitless access to scientific data.

This material is available under the Creative Commons – Attribution-NonCommercial 4.0 International (CC BY-NC 4.0).
The full terms of this license are available on: https://creativecommons.org/licenses/by-nc/4.0/legalcode

Corresponding author: Niemczyk Wiktor Antoni; Medical University of Warsaw; Fryderyka Chopina street 19, 05-822 Milanowek, Poland; Phone: +48 533745447; E-mail: wniemcz@gmail.com

Cite this article as: Niemczyk W.A., Garbacik A., Majszyk D., Bruzgielewicz A.: Penetrating neck injury. A case report; Pol Otorhino Rev 2025; 14 (4): 1–4; DOI: 10.5604/01.3001.0055.4873