INDEX COPERNICUS INTERNATIONAL

ARTYKUŁ ORYGINALNY / ORIGINAL ARTICLE

The application of electrocochleography in the diagnosis of Meniere's disease – interpretation of results and practical implications in clinical practice – case series analysis

Zastosowanie elektrokochleografii w diagnostyce choroby Ménière'a – interpretacja wyników oraz wykorzystanie w praktyce klinicznej – analiza serii przypadków

Authors' Contribution:
A – Study Design
B – Data Collection
C – Statistical Analysis
D – Data Interpretation
E – Manuscript Preparation
F – Literature Search
G – Funds Collection

Agnieszka Jasińska-Nowacka[1ABDEF], Izabela Pobożny[1BDEF], Tomasz Wojciechowski[1,2ADEF], Kazimierz Niemczyk[1ADEF]

[1]Department and Clinic of Otorhinolaryngology, Head and Neck Surgery, Medical University of Warsaw, Poland
[2]Department of Descriptive and Clinical Anatomy, Center for Biostructure Research, Medical University of Warsaw, Poland

Article history: Received: 20.10.2025 Accepted: 24.11.2025 Published: 27.11.2025

ABSTRACT:

Introduction: Meniere's disease is characterized by vertigo attacks accompanied by aural symptoms and hearing loss. Diagnosis is based on clinical symptoms, however, audiological and otoneurological tests are performed to evaluate inner ear function. Transtympanic electrocochleography (TT-ECochG) is an objective electrophysiological audiological examination useful in endolymphatic hydrops evaluation.

Aim: To present the methodology and preliminary results of the transtympanic electrocochleography (TT-EcochG) in patients with Ménière's disease.

Material and methods: The study presents TT-ECochG results in five patients with a confirmed diagnosis of Meniere's disease. The analysis included the ratio of amplitudes and areas of summations and ation potentials. The results were compared with the clinical picture and pure tone audimetry findings.

Results: Findings clearly indicative of endolymphatic hydrops were obtained in four out of five patients, while in one patient, in whom auditory symptoms predominated, the results were borderline. Abnormal TT-ECochG results in both ears were present in patient with bilateral clinical symptoms. In one case, TT-EcochG were used intraoperatively as hearing monitoring method. In another patient, the test was performed two years after surgery, with no clinically significant differences comparing with the preoperative result.

Conclusions: The preliminary analysis confirms the individual variability of MD clinical course and audiological results. Due to the diversity of examination techniques, there are no unified guidelines or widely accepted standards for the interpretation of TT-ECochG results. To achieve the highest sensitivity, a detailed interpretation of the traces should be performed. This method is noteworthy as an auxiliary diagnostic tool for assessing disease dynamics during the natural course or after treatment; however, it should not delay diagnosis or initiation of first-line therapy.

KEYWORDS: ECochG, electrocochleography, endolymphatic hydrops, Meniere's disease, vertigo

STRESZCZENIE:

Wstęp: Choroba Meniere'a charakteryzuje się atakami wirowych zawrotów głowy, którym towarzyszą objawy słuchowe oraz niedosłuch. Rozpoznanie stawiane jest na podstawie obrazu klinicznego, jednakże wykonuje się również szeroką diagnostykę audiologiczną i otoneurologiczną, która ma na celu ocenę funkcji ucha wewnętrznego. Elektrokochleografia jest obiektywnym badaniem elektrofizjologicznym przeznaczonym do diagnostyki wodniaka endolimfatycznego.

Cel: Przedstawienie metodologii oraz przykładowych wyników elektrokochleografii transtympanalnej jako pośredniej metody oceny wodniaka endolimfatycznego u pacjentów z chorobą Meniere'a.

Materiał i metody: W pracy przedstawiono wyniki badania elektrokochleografii transtympanalnej u pięciu pacjentów ze zdefiniowaną chorobą Meniere'a. Przeanalizowano stosunek amplitud oraz pól powierzchni potencjału sumacyjnego oraz czynnościowego. Wyniki zestawiono z obrazem klinicznym i wynikiem badania audiometrii tonalnej.

Wyniki: Wyniki jednoznacznie wskazujące na wodniaka endolimfatycznego uzyskano u czterech z pięciu przedstawionych chorych, natomiast u jednego pacjenta z przewagą manifestacji słuchowej wyniki były graniczne. Pacjent z obustronną manifestacją kliniczną miał także obustronnie nieprawidłowy wynik badania elektrokochleografii transtympanalnej. U jednego z pacjentów badanie wykonane było bezpośrednio przed operacją oraz jako śródoperacyjny monitoring słuchu, w trakcie neurektomii przedsionkowej z dostępu przez środkowy dół czaszki. U kolejnego pacjenta badanie elektrokochleografii wykonano także kontrolnie po dwóch latach od operacji, nie stwierdzono istotnych klinicznie różnic.

Wnioski: Analiza wstępnych wyników potwierdza zmienny osobniczo charakter choroby Meniere'a, co odzwierciedlone jest także w wynikach badań dodatkowych. Ze względu na różnorodność stosowanych technik, brakuje ujednoliconych wytycznych i powszechnie akceptowanego standardu interpretacji elektrokochleografii. W celu uzyskania najwyższej czułości należy przeprowadzić szczegółową interpretację zapisu elektrokochleografii. Jest to metoda warta uwagi jako badanie dodatkowe w trakcie diagnostyki oraz w celu oceny dynamiki w przebiegu naturalnym choroby lub po leczeniu, nie powinna jednak opóźniać postawienia rozpoznania oraz włączenia leczenia pierwszego rzutu.

SŁOWA KLUCZOWE: choroba Meniere'a, ECochG, elektrokochleografia, wodniak endolimfatyczny, zawroty głowy

ABBREVIATIONS

AAO-HNS – American Academy of Otorhinolaryngology-Head and Neck Surgery
AP – action potential
ECochG – electrocochleography
ET-ECochG – extratympanic electrocochleography
MRI – magnetic resonance imaging
PTA – pure tone average
SP – summation potential
SP/AP amp ratio – summation-to-action potential amplitude ratio
SP/AP area ratio – summation-to-action potential area ratio
T-ECochG – tympanic electrocochleography
TT-ECochG – transtympanic electrocochleography

INTRODUCTION

The typical clinical manifestation of Ménière's disease consists of recurrent episodes of vertigo with nausea and vomiting, accompanied by auditory symptoms such as tinnitus, aural fullness, and fluctuating low-frequency hearing loss [1–3].

The morphological basis of the disease was visualized with the help of microscopic techniques by Cairns et al. [4] and Yamakawa [5], who had analyzed temporal bone structures in patients with a history of Ménière's disease. The observed dilatation of the endolymphatic spaces within the inner ear was termed endolymphatic hydrops, henceforth considered a morphological exponent of the disease. Unfortunately, histopathological confirmation is only possible by post-mortem examination. Effective diagnostic tools that enable the intravital assessment of the function of inner ear structures are therefore lacking and constitute the subject of active research. A major breakthrough consisted in the ability to visualize endolymphatic hydrops on magnetic resonance imaging (MRI) using a dedicated protocol [6–8].

In addition to the episodes of vertigo, considered the most bothersome symptom, Ménière's disease is also characterized by hearing-related complaints. About one-half of patients present with a non-fully symptomatic audiological onset of the disease, resulting in difficulties in making a diagnosis within the first few months [9]. In the first phase of the disease, the hearing loss is transient, frequently appearing as a symptom heralding the onset of a full-blown vertigo episode. With the advancement of endolymphatic hydrops, the hearing loss progresses to become fixed and pantonal [2, 9]. Tinnitus and aural fullness are characterized by individually variable dynamics, and their correlation with the severity of inner ear lesions is uncertain [2, 9].

The diagnosis of Ménière's disease is made on the basis of the typical clinical presentation and the results of tonal audiometry tests [2, 3]. Advanced audiological and otoneurological diagnostics, however, are needed for the examination of hearing and balance functions; they also facilitate reproducible assessment and analysis of the dynamics in the natural course of the disease and document the effectiveness of treatment. In addition, they are crucial for a better understanding of the etiopathogenesis of Ménière's disease.

Electrocochleography (ECochG) is an objective method of measuring the potentials generated within the inner ear in response to acoustic stimuli [10]. The test can be performed using an extratympanic electrode placed within the external auditory canal (extratympanic electrocochleography [ET-ECochG]), a tympanic electrode in contact with the tympanic membrane (tympanic electrocochleography [T-ECochG]), or a transtympanic needle electrode placed in the promontory of the tympanic cavity (transtympanic electrocochleography [TT-ECochG]) [10, 11]. The assessment is based on the analysis of the summating potential (SP), derived from cochlear sensory cells, and the action potential (AP), derived from the activity of the cochlear nerve fibers.

ECochG is a tool dedicated to the diagnosis of Ménière's disease. Elevated SP to AP amplitude ratio and SP to AP area ratio are considered electrophysiological exponents of endolymphatic hydrops.

AIM

The aim of this study was to carry out an initial assessment of the applicability of TT-ECochG in the diagnosis of Ménière's disease in

Tab. I. Clinical data and the results of tonal audiometry and transtympanic electrocochleography in patients with Ménière's disease.

	CLINICAL DATA							TRANSTYMPANIC ELECTROCOCHLEOGRAPHY						
PATIENT	AGE (YEARS)	GENDER (M/F)	EAR (R/L)	DURATION OF DISEASE (YEARS)	FREQUENCY OF EPISODES*	FUNCTIONAL LEVEL ACCORDING TO AAO-HNS (1–6)	PTA (DBHL)	*SP AMP* (μV)	*AP AMP* (μV)	*SP/AP AMP RATIO*	*AP LAT* (ms)	*SP AREA*	*AP AREA*	*SP/AP AREA RATIO*
1	39	M	L	9	1	5	68.75	1.33	1.25	**1.06**	1.95	1.97	0.65	**3.01**
2	42	M	L	5/12	15	5	21.25	6.64	5.46	**1.22**	1.77	8.15	0.67	**12.18**
3	62	M	R	11	4	4	66.25	0.34	0.57	**0.60**	1.77	0.40	0.18	**2.26**
4	33	M	R	6	2	2	25.00	1.37	2.61	**0.52**	1.65	2.45	1.04	**2.35**
			L	7			55.00	0.86	1.39	**0.62**	1.93	1.11	0.40	**2.78**
5	37	M	R	7	4	5	6.25	0.43	0.97	0.44	1.80	1.03	0.55	1.88

*average monthly number of vertigo episodes in the past 6 months; M – male; F – female; R – right; L – left; AAO-HNS – American Academy of Otorhinolaryngology, Head and Neck Surgery; PTA – pure tone average threshold at 500, 1000, 2000, 4000 Hz; SP – summating potential; AP – action potential; amp – amplitude.

patients with varying clinical presentations. In order to discuss the technical aspects of the test and to provide an accurate interpretation of its results, the analysis was carried out on example cases.

MATERIAL AND METHODS

The results of TT-ECochG examinations in patients with defined Ménière's disease were analyzed in detail. The methodology and preliminary findings are presented as illustrated using five clinical case examples.

A package of audiological and otoneurological tests was performed on patients in the course of diagnostic hospitalization. Patients without contraindications to MRI scanning were subjected to an examination using a 3T scanner and a protocol dedicated to the Ménière's disease.

On the basis of the tonal audiometry results at the frequencies of 500, 1000, 2000, and 4000 Hz, the average hearing threshold (pure tone average [PTA]) values were calculated.

A dual-channel SmartBox device with SmartEP software (Intelligent Hearing Systems, FL, Miami, USA) was used to perform the TT--ECochG diagnostic tests. Each time, the TT-ECochG measurement needle electrodes (–) were inserted by an otorhinolaryngologist (after prior anesthesia of the external ear canal) through the posterior-inferior quadrant of the tympanic membrane and supported within the promontory. A foam/gel grounding electrode was placed on the skin of the forehead, in the midline above the eyes, and a foam/gel reference electrode (+) was placed above the grounding electrode, closer to the scalp border line. The impedance of the electrodes was within the normal range of 1–3 kΩ, which was achieved after degreasing and covering the patient's skin with conductive gel.

To obtain a response from TT-ECochG, crackling sound stimulation was applied at an amplitude of 80–90 dBnHL using ER3 insert earphones (Etymotic Research, Elk Grove Village, IL, USA) placed

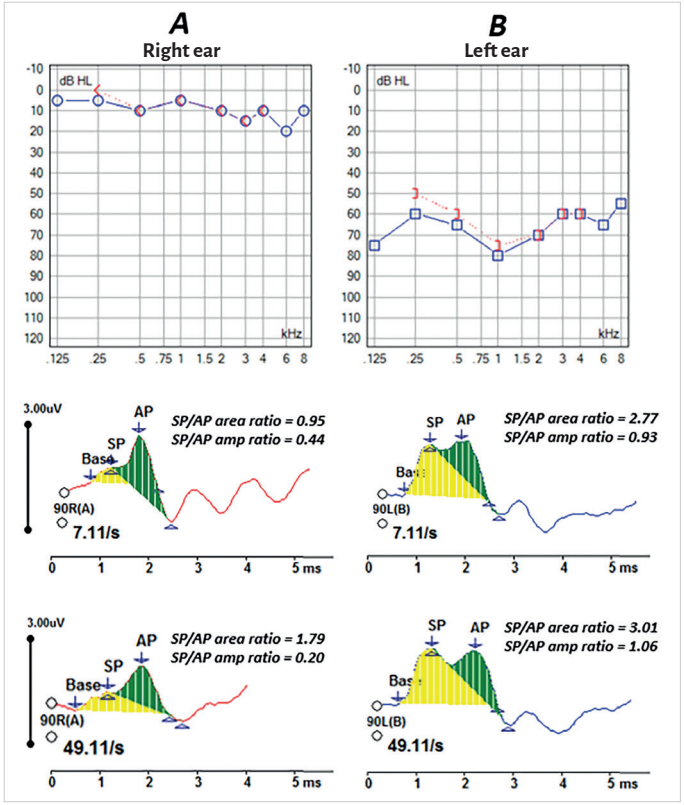

Fig. 1. Audiological findings in a patient with defined Ménière's disease of the left ear. The top panel shows the result of a tonal audiometry test. Pantonal sensorineural hearing loss of moderate degree with the PTA threshold of 68.75 dBHL can be seen in the left ear audiogram. The middle and bottom panels show the results of transtympanic electrocochleography with stimulus presentation rates of 7.11/s and 49.11/s, respectively. The analysis of SP and AP amplitudes and the amplitude ratio (SP/AP amp ratio). Obvious features of endolymphatic hydrops can be seen in the left ear chart. In the right ear, the results are within the reference limits.

within the external ear canal after the measuring needle electrode was placed against the promontory. The consecutive stimulus presentation rates were 7.11/s and 49.11/s, with the number of averaged signal samples amounting to 256, allowing for clear and reproducible responses. The stimuli were delivered with alternating polarities. The gain was ×100k, and 30–3000 Hz filters were applied.

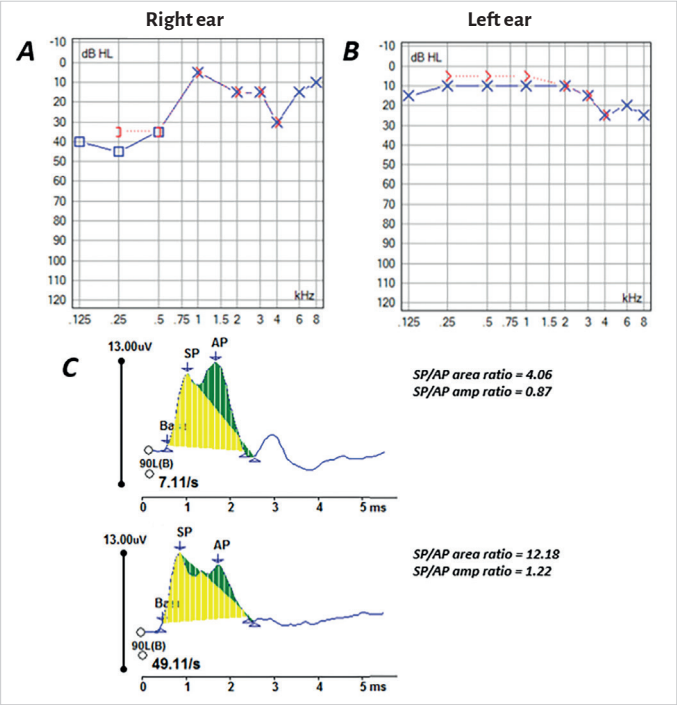

Fig. 2. Audiological findings in a patient with Ménière's disease symptoms within the left ear. The top panel shows the results of the tonal audiometry test at diagnosis (A) and one month after the left vestibular neurectomy (B). Prior to the surgery, the left ear presented with low-frequency sensorineural hearing loss with a PTA threshold of 21.25 dB HL. At follow-up, the hearing improved to reach the PTA of 13.75 dB HL. The bottom panel (C) shows the results of TT-ECochG with stimulus presentation rates of 7.11/s and 49.11/s as performed under operating theater conditions immediately before vestibular nerve transection surgery. The analysis of SP and AP amplitudes and the amplitude ratio (SP/AP amp ratio). Obvious features of endolymphatic hydrops can be seen in the left ear chart.

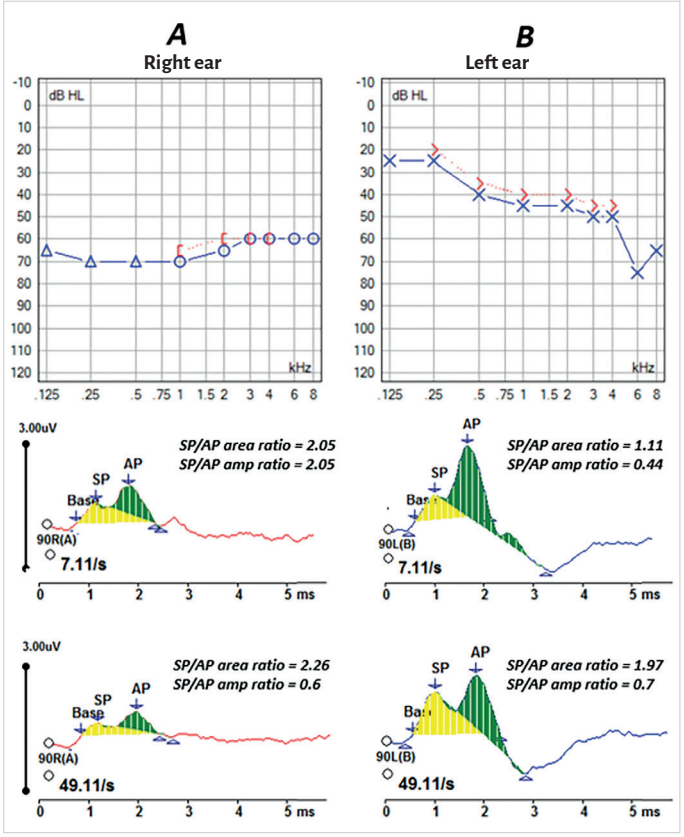

Fig. 3. Audiological findings in a patient with defined Ménière's disease of the right ear. The top panel shows the result of a tonal audiometry test. Pantonal sensorineural hearing loss of moderate degree with the pure tone average threshold of 68.75 dBHL can be seen in the right ear audiogram. High-frequency sensorineural hearing loss can also be seen in the asymptomatic left ear. The middle and bottom panels show the results of transtympanic electrocochleography with stimulus presentation rates of 7.11/s and 49.11/s, respectively. The analysis of SP and AP amplitudes and the amplitude ratio (SP/AP amp ratio). Obvious features of endolymphatic hydrops can be seen in the right ear chart. In the right ear, the results are within the reference limits. Left ear presented with an abnormal result at the stimulus presentation rate of 49.11/s.

The analysis time window was 12.8 ms. The choice of this window duration was based on physiological and measurement parameters (time window adequate for observation of all TT-ECochG signals, no secondary overlapping of waves, no conflict with the recording filters, etc.).

The SP and AP potentials and their amplitude, as well as area ratios, were calculated using the SmartEP software. The summation-to-action potential amplitude ratio (SP/AP amp ratio) of > 0.5 and summation-to-action potential area ratio (SP/AP area ratio) of > 1.94 were considered indicative of endolymphatic hydrops [9].

RESULTS

The article presents the cases of five patients as examples for the analysis. The patients' clinical data are presented in Tab. I.

Patient #1

Patient #1 was a 39-year-old man who had been experiencing the symptoms of Ménière's disease in the left ear for nine years. The first clinical manifestation consisted in a vertigo episode lasting several hours, accompanied by aural fullness. The hearing loss was initially fluctuating and preceded the vertigo episodes to become fixed and pantonal after several years. Since the onset of the disease, the patient had been taking betahistine at a standard dose; two years before presentation, he also had a pressure relief drain placed in his symptomatic ear. During diagnostic hospitalization, the patient was in remission, with moderate hearing loss found on tonal audiometry (PTA of 68.75 dBHL) (Fig. 1B.). TT-ECochG examination showed a significant increase in the SP/AP amplitude and area ratios typical for endolymphatic hydrops (Tab. I., Fig. 1B.).

Patient #2

Patient #2 was a 42-year-old man who had been experiencing symptoms of Ménière's disease for 5 months. The first clinical manifestation consisted in a severe vertigo episode with nausea and vomiting, as well as hearing loss and noise in the left ear. The patient suffered from persistent attacks that impeded daily functioning (Tab. I.). The patient had received modified-dose betahistine and hydrochlorothiazide. A series of transtympanic steroid therapy courses had also been applied. Tonal audiometry confirmed low-frequency sensorineural hearing loss within the left ear (Fig. 2A.). The endolymphatic hydrops were confirmed by an MRI scan acquired using a dedicated protocol. Due to the lack of satisfactory clinical improvement, the patient was qualified for surgical treatment. The aggressive course of the disease preventing

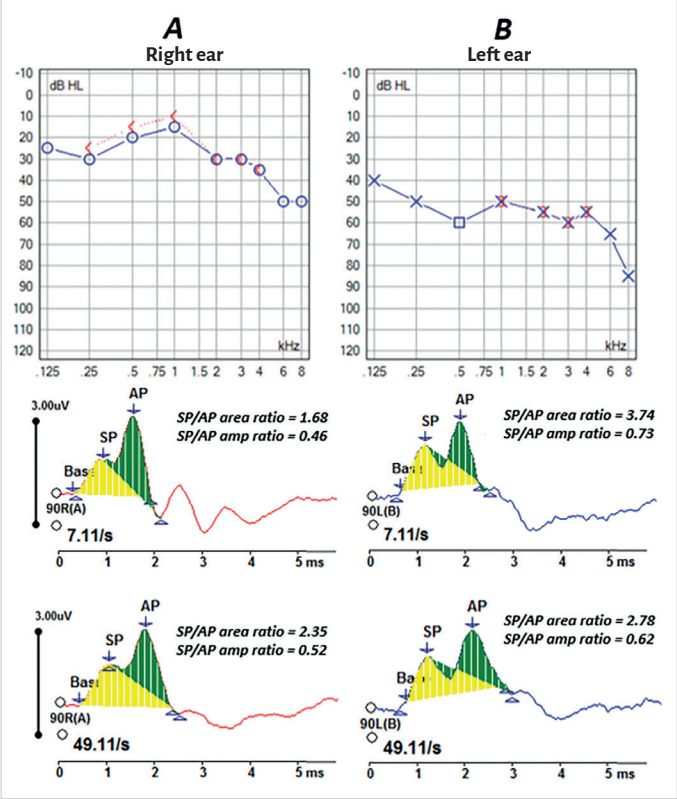

Fig. 4. Audiological findings in a patient with bilateral Ménière's disease symptoms. The top panel shows the result of a tonal audiometry test. Sensorineural hearing loss of moderate degree with the pure tone average threshold of 55 dBHL can be seen in the left ear audiogram. The right ear presents with a mild hearing loss with the pure tone average threshold of 25 dB HL. The middle and bottom panels show the results of transtympanic electrocochleography with stimulus presentation rates of 7.11/s and 49.11/s, respectively. The analysis of SP and AP amplitudes and the amplitude ratio (SP/AP amp ratio). Obvious features of endolymphatic hydrops within the left ear can be seen in both protocols. In the right ear, abnormal results were obtained at the stimulus presentation rate of 49.11/s.

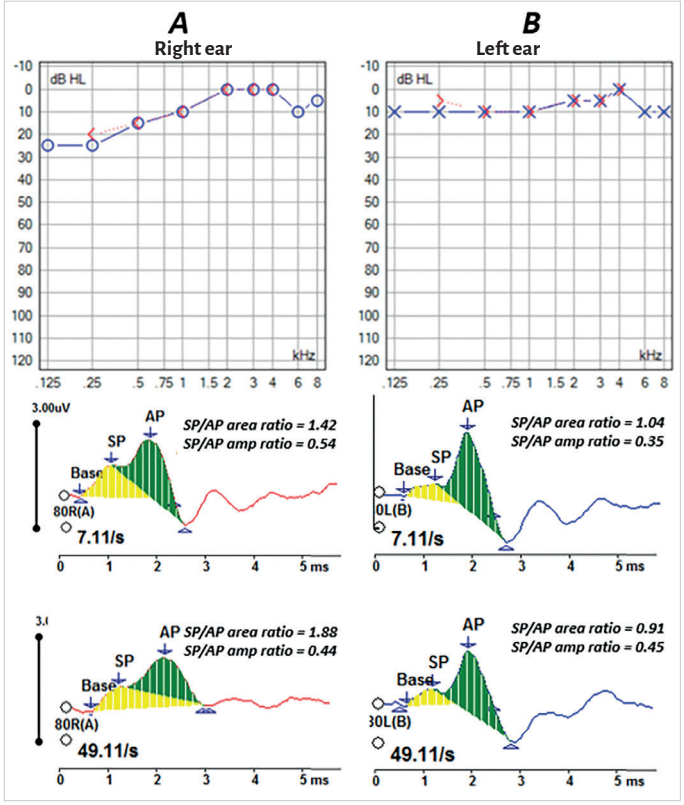

Fig. 5. Audiological findings in a patient with Ménière's disease of the right ear. The top panel shows the result of a tonal audiometry test. The right ear presents with a normal pure tone average threshold of 6.25 dB HL, with a 25 dBHL threshold for low-frequency tones. The middle and bottom panels show the results of transtympanic electrocochleography with stimulus presentation rates of 7.11/s and 49.11/s, respectively. The analysis of SP and AP amplitudes and the amplitude ratio (SP/AP amp ratio). In relation to the right ear, the borderline result as obtained for the evaluation of the SP/AP amp ratio for stimulation frequency of 7.11/s alone meets the diagnostic criteria of an endolymphatic hydrops. In the left ear, the results are within the reference limits.

everyday professional and family functioning was the crucial reason behind the patient's decision to undergo radical treatment. Selective transection of the vestibular nerves was performed from the middle cranial fossa access, with intraoperative monitoring of hearing by TT-ECochG. Examination performed within the operating theater settings immediately before the surgery showed SP/AP amplitude and area ratio results typical of advanced endolymphatic hydrops (Tab. I., Fig. 2C.). One month after surgery, a follow-up hearing test was performed to show clinically significant improvement – the hearing in the operated ear was within reference limits, with PTA threshold at 13.75 dB HL (Fig. 2B.). As of the present, the patient remains under the care of the hospital's outpatient clinic, with further appointments and post-operative examinations pending.

Patient #3

Patient #3 was a 62-year-old man with a history of Ménière's disease of the right ear encompassing a period of 11 years. The first symptoms consisted in tinnitus and aural fullness, followed by the first typical episode of vertigo one year later. After a period of remission, the clinical course of the disease worsened (Tab. I.). The patient was taking betahistine in a chronic fashion. A tonal audiometry test performed during diagnostic hospitalization confirmed pantonal sensorineural hearing loss of moderate degree (Fig. 3A.). Due to the condition after hip alloplasty, a 3T MRI scan to visualize the endolymphatic hydrops was contraindicated. The TT-ECochG study was confirmative of Ménière's disease on the right side (Tab. I., Fig. 3A.). However, an abnormal result was also obtained using one of the protocols in the asymptomatic ear (Fig. 3B.).

Patient #4

Patient #4 was a 33-year-old man with bilateral Ménière's disease. The first symptoms had occurred seven years before the diagnostic hospitalization within the left ear and consisted of sudden low-frequency sensorineural hearing loss with aural fullness. After a year, the right ear was also affected with similar complaints. Episodes of dizziness with nausea and vomiting were preceded by subjective hearing deterioration. The patient received conservative treatment with betahistine and diuretics, as well as repeated series of transtympanic steroid therapy courses followed by satisfactory clinical improvements. Tonal audiometry as performed in the remission period confirmed moderate sensorineural hearing loss in the left ear (Fig. 4B.) and a slight sensorineural hearing loss in the right ear (Fig. 4A.). ECochG results were indicative of the presence of endolymphatic hydrops in both the left and the right ear (Tab. I., Fig. 4..), correlating with bilateral endolymphatic hydrops visualized on MRI scans.

Patient #5

The last patient was a 37-year-old man with a history of recurrent, low-frequency sudden sensorineural hearing loss within the right ear. After six years of auditory manifestations, the patient experienced the first episode of vertigo which was henceforth to recur with prodromal aggravation of tinnitus and aural fullness. The patient received conservative and transtympanic treatments. Tonal audiometry exam as performed in the remission period revealed only isolated hearing deterioration at low-frequency tones (Fig. 5A.). The TT-ECochG results were borderline (Tab. I., Fig. 5A.). Endolymphatic hydrops was revealed by the MRI scan of the right ear. Due to aggressive clinical exacerbation and severe vertigo attacks, the patient was qualified for surgery. At the follow-up visit, two years after the surgery, the hearing assessments were repeated to reveal hearing deterioration within the low and high frequency ranges, with the PTA threshold of 22.5 dB HL (Fig. 6A.). In the TT-ECochG exam, elevated values of the SP/AP amplitude ratio persisted with the SP/AP area ratio being within reference limits (Fig. 6A.).

DISCUSSION

ECochG provides an objective method for the assessment of the auditory organ, offering the possibility of intravital diagnosis of endolymphatic hydrops. The test can be performed using various types of electrodes, placed within the external auditory canal, against the tympanic membrane, or within the promontory of the tympanic cavity.

In this study, ECochG measurements were performed transtympanically, using a needle electrode placed against the promontory. The method facilitates acquisition of relatively high potential amplitudes and is therefore considered the most accurate diagnostic modality of the ECochG technique [11–14]. The main limitation of the method in question consists in its invasive nature and the need to insert the needle electrode through the tympanic cavity, which is sometimes associated with discomfort or pain for the patient despite the use of local anesthesia [15, 16]. In a prospective questionnaire study, a group of 36 patients was surveyed for pain severity during the various stages of the examination, the overall impression of the test, and willingness to undergo the examination again. The average severity of pain experienced during the insertion of the electrode through the tympanic membrane was 3.83 on a scale of 0 to 10, while the pain during the test itself was rated at an average of 2.22 on the same scale. Patients' overall impression of the TT-ECochG test was rated an average of 1.47 on a scale of 0 to 10, which corresponded to good tolerance of the procedure. As many as 97.22% of the surveyed patients would opt for reexamination if needed. The authors also analyzed the records of 205 patients having undergone ECochG for potential complications of the procedure. One case of persistent tympanic membrane perforation and two cases of otitis media were described in the study cohort. Three patients reported ear pain lasting up to five days after the exam [15].

The reported sensitivity of ECochG in the diagnosis of Ménière's disease ranges widely from 47.6 to 92% [9, 14, 18, 19]. These discrepancies are primarily due to the differences in methodology and the heterogeneity of the examined patient groups. Measurements are also significantly affected by the position of the needle electrode. In a study on a group of 10 patients with tympanic membrane perforation and a negative history of endolymphatic hydrops symptoms, the results of the exam were analyzed according to the electrode placement site. The values of the SP potential amplitude varied by 100–500% depending on the position of the needle electrode within the same tested ear. The results indicate that the positioning of the electrode has a significant effect on SP recording, and therefore comparison of results with those obtained when the needle electrode is inserted through an intact membrane is fraught with a high risk of error [19].

The greatest difficulty in interpreting the ECochG results consists in the lack of established diagnostic criteria. Depending on the established cutoff value, the SP/AP amplitude ratio can indicate the presence of endolymphatic hydrops after crossing a threshold of 0.3 to 0.5 [9, 11, 17]. For higher sensitivity of the test, the SP and AP area ratio is also analyzed in addition to the amplitude ratio. An elevated SP/AP area ratio beyond the cutoff value of 1.94 is considered an additional electrophysiological exponent of endolymphatic hydrops [9, 11]. Within the presented case series, borderline results were present in one patient (Patient #5), whose disease had started with recurrent episodes of sudden sensorineural hearing loss. In a retrospective study conducted on a clinic's material, the sensitivity of ECochG reached 93.48% after both the SP/AP amplitude and area ratios, as well as the difference in AP latency depending on the polarity of the stimulus (con-rar AP latency shift) were taken into account [9]. However, the results of observational studies were not confirmed in a meta-analysis of a total of 5 studies on 315 patients, which showed no significant advantage of using the combined criteria, including the assessment of SP/AP amplitude and area ratios over a basic protocol consisting in the assessment of the SP/AP amplitude ratio alone [14].

Findings characteristic of Ménière's disease are most frequently observed in patients during disease exacerbation periods or during vertigo episodes [20]. In addition, the diagnostic value of ECochG may be limited in the early stages of the disease, as the results in patients with Ménière's disease are not significantly different from asymptomatic controls during the first six months after diagnosis [21]. The results obtained by ECochG, as a method designed to confirm the presence of endolymphatic hydrops, correlate with the clinical presentation and the results of other audiological and otoneurological examinations [9, 17, 20, 22, 23]. Due to the unpredictable, fluctuating course of Ménière's disease, the ECochG result does not correlate with the severity of the patient's complaints and functional level [9]. Also, a high degree of inter-individual variability in the clinical course and the results of ECochG is evident even in the small group of patients presented in the current study. Literature reports analyzed the relationship between the ECochG results and the PTA thresholds on tonal audiometry. Statistically significant correlations between the PTA threshold and ECochG results obtained with an electrode placed within the external ear canal were reported on in a paper discussing findings in patients with hearing loss and a healthy population [24]. In addition, the thresholds at each frequency correlated with the electrophysiologically determined values.

Until the development of the MRI technology, ECochG was considered the main modality for intravital, indirect assessment of the progression of endolymphatic hydrops. Today, with the ability to image the inner ear structures, correlations between the advancement of endolymphatic hydrops as seen on MRI scans and the ECochG results can be analyzed [25, 26]. ECochG provides a valuable diagnostic option for endolymphatic hydrops in patients with contraindications to an MRI scan using the protocol dedicated to the diagnosis of Ménière's disease.

TT-ECochG is used as a method for intraoperative monitoring of hearing during surgeries to remove small tumors of the vestibulocochlear nerve [27]. Similarly, TT-ECochG can be performed during vestibular neurectomy as performed from the middle cranial fossa access, as in the case of Patient #3. A tonal audiometry exam performed one month after surgery revealed normal hearing, suggesting the significant importance of intraoperative monitoring in the preservation of hearing in the operated ear.

Ménière's disease follows a fluctuating course with periods of exacerbation and spontaneous remission. ECochG can be a useful tool for indirect assessment of changes in the severity of endolymphatic hydrops in the natural course of the disease, as well as during and after the treatment. A limitation, however, consists in the results depending on the electrode placement site and discrepancies between individual results due to small displacements of the needle electrode in the same patient [19].

CONCLUSIONS

ECochG has been part of the additional armamentarium for the diagnosis of Ménière's disease for many years. Due to the variety of testing techniques and interpretation criteria, no unified guideline or universally accepted interpretation standards have been defined as of yet. In order to obtain the highest sensitivity, the ECochG records must be subjected to detailed interpretation, including the evaluation of the SP/AP area ratio in addition to the SP/AP amplitude ratio. ECochG is noteworthy as an auxiliary diagnostic tool for assessing the dynamics of the disease during its natural course or following a treatment. It can also be used in patients in whom imaging-based confirmation of endolymphatic hydrops is not possible due to contraindications.

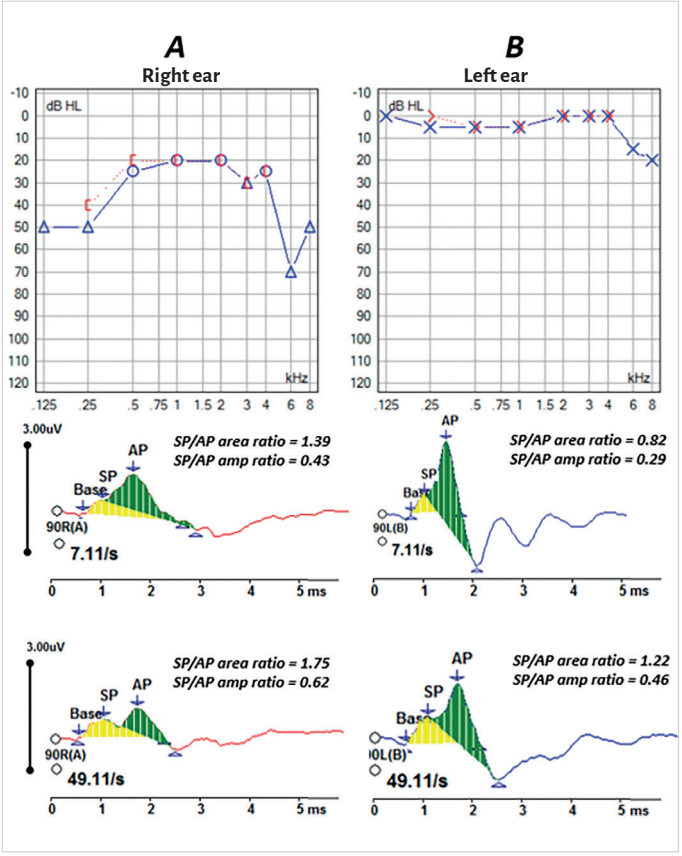

Fig. 6. Audiological findings in a patient with Ménière's disease of the right ear as acquired two years after vestibular neurectomy from the middle cranial fossa access. The top panel shows the result of a tonal audiometry test. The left ear presented with low-frequency sensorineural hearing loss with a PTA threshold of 22.5 dB HL. The middle and bottom panels show the results of transtympanic electrocochleography with stimulus presentation rates of 7.11/s and 49.11/s, respectively. The analysis of SP and AP amplitudes and the amplitude ratio (SP/AP amp ratio). In relation to the right ear, the borderline result as obtained for the evaluation of the SP/AP amp ratio for stimulation frequency of 49.11/s alone meets the diagnostic criteria of endolymphatic hydrops. In the left ear, the results are within the reference limits.

Despite the characteristic clinical manifestation, the diagnosis of Ménière's disease is frequently made several years after the onset of the first symptoms. It should therefore be emphasized that the extensive diagnostic options available only at reference centers, including the ECochG, are not a prerequisite for diagnosis and should not delay the inclusion of treatment.

REFERENCES

1. Meniere P.: Sur une forme particulière de surdité grave dépendant d'une lésion de l'oreille interne. Gazette Médicale de Paris., 1861; 16: 29.
2. Sajjadi H., Paparella MM.: Meniere's disease. Lancet., 2008; 372(9636): 406–414. doi: 10.1016/S0140-6736(08)61161-7.
3. Basura G.J., Adams M.E., Monfared A. et al.: Clinical practice guideline: Ménière's disease – executive summary. Otolaryngol Head Neck Surg., 2020; 162(4): 415–434. doi: 10.1177/0194599820909438.
4. Hallpike C.S., Cairns H.: Observations on the pathology of Ménière's syndrome. Proc R Soc Med., 1938; 31(11): 1317–1336.
5. Yamakawa K.: Temporal bone histopathology of Meniere's patient. Presented at: Annual Meeting of the Oto-Rhino-Laryngological Society of Japan, Japan 1938.
6. Naganawa S., Nakashima T.: Visualization of endolymphatic hydrops with MR imaging in patients with Ménière's disease and related pathologies: current status of its methods and clinical significance. Jpn J Radiol., 2014; 32(4): 191–204. doi: 10.1007/s11604-014-0290-4.
7. Wnuk E., Lachowska M., Jasińska-Nowacka A., Maj E, Rowiński O., Niemczyk K.: Detailed insight into magnetic resonance assessment of Ménière's disease: description of methodology and imaging findings in a case series. Pol J Radiol., 2023; 88: e132–e139. doi: 10.5604/01.3001.0016.2701.
8. Bernaerts A., Vanspauwen R., Blaivie C. et al.: The value of four-stage vestibular hydrops grading and asymmetric perilymphatic enhancement in the diagnosis of Menière's disease on MRI. Neuroradiology., 2019; 61(4): 421–429. doi: 10.1007/s00234-019-02155-7.
9. Jasińska-Nowacka A., Lachowska M., Niemczyk K.: Detailed clinical characteristics and their correlation with diagnostic test results in patients with defined Meniere's disease. Otolaryngol Pol., 2023; 77(2): 1–5. doi: 10.5604/01.3001.0016.2663.

10. Lempert J., Wever E.G., Lawrence M.: The cochleogram and its clinical application. Arch Otolaryngol., 1947; 45(1): 61–67. doi: 10.1001/archotol.1947.00690010068005.
11. Lamounier P., Gobbo D.A., Souza T.S., Oliveira C.A., Bahmad F. Jr.: Electrocochleography for Ménière's disease: is it reliable? Braz J Otorhinolaryngol., 2014; 80(6): 527–532. doi: 10.1016/j.bjorl.2014.08.010.
12. Mori N., Asai H., Sakagami M., Matsunaga T.: Comparison of summating potential in Menière's disease between trans- and extratympanic electrocochleography. Audiology., 1987; 26(6): 348–355. doi: 10.3109/00206098709081589.
13. Dobbs A., Krueger W., Bishop S.: Comparison of transtympanic and extratympanic electrocochleography. Int J Otolaryngol Head Neck Surg., 2013; 2(5): 160–164. doi: 10.4236/ijohns.2013.25035.
14. Ayub A., Qi L., Nunez D.A.: A systematic review and meta-analysis of extratympanic electrocochleography in Ménière's disease diagnosis. Int J Audiol., 2019; 58(9): 533–540. doi: 10.1080/14992027.2019.1606947.
15. Ng M., Srireddy S., Horlbeck D.M., Niparko J.K.: Safety and patient experience with transtympanic electrocochleography. Laryngoscope., 2001; 111(5): 792–795. doi: 10.1097/00005537-200105000-00007.
16. Bath A.P., Beynon G.J., Moffat D.A., Baguley D.M.: Effective anaesthesia for transtympanic electrocochleography. Auris Nasus Larynx., 1998; 25(2): 137–141. doi: 10.1016/S0385-8146(97)10036-0.
17. Kim H.H., Kumar A., Battista R.A., Wiet R.J.: Electrocochleography in patients with Meniere's disease. Am J Otolaryngol., 2005; 26(2): 128–131. doi: 10.1016/j.amjoto.2004.11.005.
18. Hornibrook J.: Tone-burst electrocochleography for the diagnosis of clinically certain Meniere's disease. Front Neurosci., 2017; 11: 301. doi: 10.3389/fnins.2017.00301.
19. Deans J.A., Hill J., Birchall J.P. et al.: The effect of electrode position in electrocochleography. Clin Otolaryngol Allied Sci., 1996; 21(4): 317–323. doi: 10.1111/j.1365-2273.1996.tb01078.x.
20. Ferraro J.A., Arenberg I.K., Hassanein R.S.: Electrocochleography and symptoms of inner ear dysfunction. Arch Otolaryngol., 1985; 111(2): 71–74. doi: 10.1001/archotol.1985.00800020039007.
21. Oh K.H., Kim K.W., Chang J. et al.: Can we use electrocochleography as a clinical tool in the diagnosis of Meniere's disease during the early symptomatic period? Acta Otolaryngol., 2014; 134(8): 771–775. doi: 10.3109/00016489.2014.908333.
22. Conlon B.J., Gibson W.P.: Electrocochleography in the diagnosis of Meniere's disease. Acta Otolaryngol., 2000; 120(4): 480–483. doi: 10.1080/00016480750045965.
23. Devaiah A.K., Dawson K.L., Ferraro J.A., Ator G.A.: Utility of area curve ratio electrocochleography in early Meniere disease. Arch Otolaryngol Head Neck Surg., 2003; 129(5): 547–551. doi: 10.1001/archotol.129.5.547.
24. Bozkurt H.K., Karaçaylı C., Satar B.: Can electrocochleography predict pure tone thresholds without correction factors? J Int Adv Otol., 2025; 21(4): 1–5. doi: 10.5152/iao.2025.241697.
25. Yamamoto M., Teranishi M., Naganawa S. et al.: Relationship between the degree of endolymphatic hydrops and electrocochleography. Audiol Neurootol., 2010; 15(4): 254–260. doi: 10.1159/000258681.
26. Jasińska A., Lachowska M., Wnuk E. et al.: Correlation between magnetic resonance imaging classification of endolymphatic hydrops and clinical manifestations and audiovestibular test results in patients with definite Ménière's disease. Auris Nasus Larynx., 2022; 49(1): 34–45. doi: 10.1016/j.anl.2021.03.027.
27. Pobożny I., Lachowska M., Bartoszewicz R., Niemczyk K.: Detailed insight into transtympanic electrocochleography (TT-ECochG) and direct cochlear nerve action potential (CNAP) for intraoperative hearing monitoring in patients with vestibular schwannoma – methodology of measurements and interpretation of results. Otolaryngol Pol., 2020; 74(6): 1–8. doi: 10.5604/01.3001.0014.3668.

Table of content: https://otorhinolaryngologypl.com/issue/17010 Tables: 1 Figures: 6 References: 27

Copyright: Some rights reserved: Polish Society of Otorhinolaryngologists Head and Neck Surgeons. Published by Index Copernicus Sp. z o.o.

Competing interests: The authors declare that they have no competing interests.

The content of the journal „Polish Society of Otorhinolaryngologists Head and Neck Surgeons" is circulated on the basis of the Open Access which means free and limitless access to scientific data.

This material is available under the Creative Commons – Attribution-NonCommercial 4.0 International (CC BY-NC 4.0).
The full terms of this license are available on: https://creativecommons.org/licenses/by-nc/4.0/legalcode

Corresponding author: Tomasz Wojciechowski (ORCID: 0000-0002-3639-4422); Department and Clinic of Otorhinolaryngology, Head and Neck Surgery, Medical University of Warsaw; Banacha street 1a, 02-097 Warsaw, Poland; E-mail: tomasz.wojciechowski@wum.edu.pl

Cite this article as: Jasinska-Nowacka A., Pobozny I., Wojciechowski T., Niemczyk K.: The application of electrocochleography in the diagnosis of Meniere's disease – interpretation of results and practical implications in clinical practice – case series analysis; Pol Otorhino Rev 2025; 14 (4): 1–8; DOI: 10.5604/01.3001.0055.4507