INDEX COPERNICUS INTERNATIONAL

Feasibility of Hearing Monitoring using ASSR during One-Stage Tympanoplasty and Ossicular Chain Reconstruction – preliminary report

Możliwości monitorowania słuchu z wykorzystaniem ASSR podczas jednoetapowej tympanoplastyki i rekonstrukcji łańcucha kosteczek słuchowych – badania wstępne

Authors' Contribution:
A – Study Design
B – Data Collection
C – Statistical Analysis
D – Data Interpretation
E – Manuscript Preparation
F – Literature Search
G – Funds Collection

Askhat Khamidulin[1,2ABCDEF], Achala Kamath[1,3DE], Robert Bartoszewicz[1BE], Kazimierz Niemczyk[1BEF]

[1]Department of Otorhinolaryngology, Head and Neck Surgery, Medical University of Warsaw, Poland
[2]State Municipal Enterprise on the Right of Economic Management "City Clinical Hospital No. 1" Kazakhstan, Shymkent
[3]Dr.Kirtane's Clinic, Amar Bhavan, Mumbai, India

Article history: Received: 01.11.2025 Accepted: 01.12.2025 Published: 23.03.2026

ABSTRACT:

Introduction: Ossiculoplasty and stapedectomy are well-known techniques for surgically correcting conductive hearing loss. However, their effectiveness can only be assessed after surgery, particularly after the ear has healed. Measuring the function of the conductive system during reconstruction encounters various methodological challenges and requires a dedicated surgical technique. In two-stage ossiculoplasty procedures (second-look surgery), when the tympanic membrane was intact, the usefulness of laser vibrometry and electrophysiological measurements for optimizing ossicular chain reconstruction has been confirmed. However, clinical situations in which ossiculoplasty is performed with the tympanic membrane intact are rare. The idea of monitoring the function of the reconstructed middle ear conduction system during every hearing-improving procedure is very attractive. However, no uniform strategy has yet been developed in this regard. Few publications present various assumptions of the monitoring techniques as well as technical and methodological details. The application of current monitoring measurement methods to single-stage operations requires solving additional problems so that measurements of the newly reconstructed conduction system can be carried out and their effectiveness confirmed.

Aim: To evaluate the feasibility of intraoperative hearing monitoring using Auditory Steady-State Responses (ASSR) during one-stage tympanoplasty and in revision stapedectomy.

Materials and methods: 4 patients with chronic otitis media underwent ossiculoplasty with autologous bone prostheses (3 cortical bone, 1 incus) and one patient had stapedectomy due to revision of otosclerosis. In patients with chronic otitis media, simultaneous reconstruction of the tympanic membrane with perichondrium was performed. Intraoperative hearing monitoring was performed using ASSR. In all cases, the measuring electrode was placed close to the round window after performing a posterior tympanotomy. A high skin incision of the external auditory canal allowed for the microphone to be placed. Before measurements, a perforated silicone sheet was placed on the reconstructed tympanic membrane to additionaly stabilize the reconstructed tympanic membrane surface. Intraoperative measurements were compared with pure-tone audiometry obtained before surgery and 3 months postoperatively.

Results: In all cases, improvement in hearing function was confirmed by postoperative audiometry and intraoperative ASSR recordings. A reduction in the air–bone gap and a positive trend in auditory thresholds were observed.

Conclusions: Intraoperative hearing monitoring with ASSR during one-stage tympanoplasty and revision stapedectomy is feasible and a promising method for confirming surgical outcomes in conductive hearing loss. Further studies are needed to standardize the methodology and validate its clinical significance.

KEYWORDS: ASSR, chronic otitis media, intraoperative hearing monitoring, ossiculoplasty, revision stapedectomy, tympanoplasty

TRESZCZENIE:

Wprowadzenie: Ossikulopastyka i stapedektomia są dobrze znanymi technikami chirurgicznej korekcji przewodzeniowego ubytku słuchu. Skuteczność wymienionych metod można jednak ocenić dopiero po zabiegu, a zwłaszcza po wygojeniu ucha. Pomiar funkcji układu przewodzącego podczas rekonstrukcji napotyka różne wyzwania metodologiczne i wymaga specjalistycznej techniki chirurgicznej. W operacjach dwuetapowych, gdy błona bębenkowa była ustabilizowana, potwierdzono

 DOI: 10.5604/01.3001.0055.5058

znaczną przydatność wibrometrii laserowej i pomiarów elektrofizjologicznych do optymalizacji rekonstrukcji łańcucha kosteczek słuchowych. Jednakże sytuacje kliniczne, w których wykonuje się ossikuloplastykę z nienaruszoną błoną bębenkową, są rzadkie. Idea monitorowania funkcji zrekonstruowanego układu przewodzącego ucha środkowego podczas każdego zabiegu poprawiającego słuch jest nader atrakcyjna. Dotychczas nie opracowano jednolitej strategii w tym zakresie. Niewiele publikacji przedstawia różne założenia dotyczące technik monitorowania, a także szczegóły techniczne i metodologiczne. Zastosowanie obecnych metod pomiarów monitorujących w operacjach jednoetapowych wymaga rozwiązania szeregu problemów, co jest niezbędnym warunkiem skutecznego przeprowadzenia pomiarów zrekonstruowanego układu przewodzącego i potwierdzenia ich skuteczności.

Cel: Celem pracy jest ocena wykonalności śródoperacyjnego monitorowania słuchu z wykorzystaniem słuchowych odpowiedzi stanu ustalonego (ASSR) podczas jednoetapowej tympanoplastyki oraz w rewizji po stapedektomii.

Materiał i metody: U 4 pacjentów z przewlekłym zapaleniem ucha środkowego wykonano ossikuloplastykę z użyciem autologicznych protez kostnych (z kości korowej wykonano 3 protezy, z kowadełka wykonano 1 protezę). U piątego pacjenta wykonano reoperację otosklerozy. U pacjentów z przewlekłym zapaleniem ucha środkowego wykonano jednoczesną rekonstrukcję błony bębenkowej z zastosowaniem ochrzęstnej. Śródoperacyjny monitoring słuchu przeprowadzono z wykorzystaniem ASSR. We wszystkich przypadkach elektrodę pomiarową umieszczono w pobliżu okienka okrągłego po wykonaniu tylnej tympanotomii. Wysokie nacięcie skóry przewodu słuchowego zewnętrznego umożliwiło odpowiednie umieszczenie mikrofonu. Przed wykonaniem pomiarów na zrekonstruowanej błonie bębenkowej umieszczono perforowaną folię silikonową, aby dodatkowo ustabilizować jej powierzchnię. Pomiary śródoperacyjne porównano z audiometrią tonalną wykonaną przed operacją, a następnie 3 miesiące po operacji.

Wyniki: We wszystkich przypadkach poprawę funkcji słuchowej potwierdzono w pooperacyjnym badaniu audiometrii tonalnej oraz w badaniu śródoperacyjnego zapisu ASSR. Zaobserwowano redukcję rezerwy ślimakowej wraz z pozytywnym trendem w zakresie progów słyszenia.

Wnioski: Śródoperacyjne monitorowanie słuchu z wykorzystaniem ASSR podczas jednoetapowej tympanoplastyki i stapedektomii jest wykonalne i stanowi jednocześnie obiecującą metodę potwierdzania wyników operacji w przypadku przewodzeniowego ubytku słuchu. Konieczne są dalsze badania w celu ujednolicenia metodologii i potwierdzenia jej znaczenia klinicznego.

SŁOWA KLUCZOWE: ASSR, jednoetapowa tympanoplastyka, monitorowanie śródoperacyjne, ossikuloplastyka, rewizyjna stapedektomia

ABBREVIATIONS

ABG – air-bone gap
ABR – Auditory Brainstem Response
ASSR – auditory steady-state response
EAC – external auditory canal
LDV – laser Doppler vibrometry
MERI – Middle Ear Index Risk
METF – middle ear transfer function
PT – posterior tympanotomy
RSG – repeating sequence gated
SFE – sound field earphone

INTRODUCTION

Ossiculoplasty and stapedectomy are well-known techniques for improving hearing. The main aim of ossiculoplasty is to optimally improve hearing. However, factors affecting the results include: the status of the middle ear eustachian tube, surgical technique, type of prosthesis and ossicular remnants [1–3]. This is why hearing restoration in patients with chronic otitis media remains a challenging task in modern otologic surgery. Despite advances in tympanoplasty, achieving stable functional results is often difficult [1, 4]. In many cases, the ABG (air-bone gap) is more than 20 dB, which has been attributed to a previous history of surgeries, cholesteatoma, or higher MERI values [5].

The disadvantage of all surgical procedures performed on the conductive system of the middle ear is that their effectiveness can only be assessed after surgery, especially after the ear has healed. Measuring the function of the conduction system during its reconstruction encounters various methodological challenges and requires a dedicated surgical technique. In two-stage surgeries, the usefulness of laser vibrometry and electrophysiological measurements for optimizing ossicular chain reconstruction has been confirmed [4, 6–9].

Single-stage surgeries require resolving additional challenges to conduct measurements of the newly reconstructed conduction system and subsequently confirm their effectiveness.

At our institution, we applied intraoperative monitoring of hearing, assessing the position of the prosthesis using ASSR (auditory steady-state response) and LDV (laser Doppler vibrometry) during the second-stage tympanoplasty. It was proved that it could be implemented to study ossicular chain prostheses functioning and coupling, as well as for real-time monitoring [6, 8, 10–15].

Despite good correlation between ASSR and LDV, only ASSR confirms the functioning of the entire hearing system [4, 15–17].

AIM

This study aimed to evaluate the feasibility of one-stage tympanoplasty when the whole reconstruction is performed during the first operation using only ASSR. Another aim was to evaluate such a monitoring performed in revision stapedectomy.

Tab. I. Clinical data of 5 patients.

PATIENT NO	AGE/SEX	SYMPTOMS	DISCHARGE +/-	PERFORATION LOCATION	CLINICAL DIAGNOSIS
1	63/M	Hearing loss right, tinnitus	–	In the upper quadrant	Chronic otitis media with cholesteatoma
2	64/F	Hearing loss right	–	Subtotal	Chronic otitis media
3	29/F	Hearing loss left	–	Subtotal	Chronic otitis media
4	14/F	Hearing loss left	–	Subtotal	Chronic otitis media
5	69/M	Hearing loss right	–	Normal	Otosclerosis

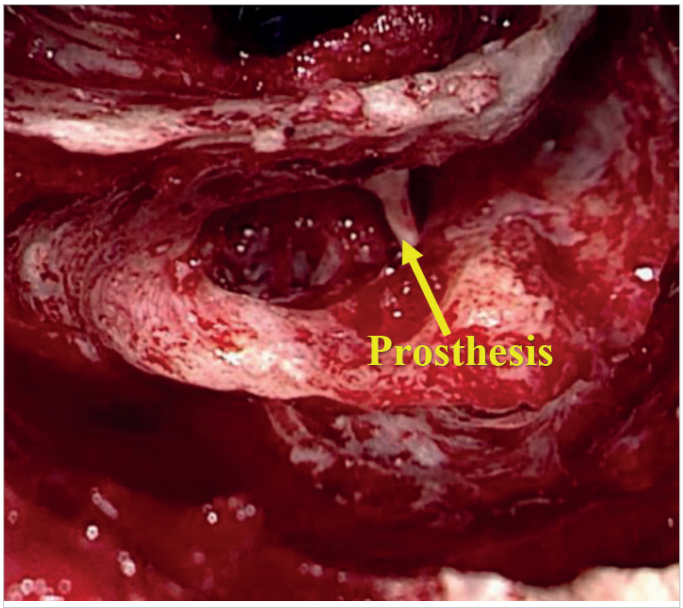

Fig. 1. Left ear – Prosthesis insertion via extended posterior tympanotomy reconstructing the malleus footplate assembly (MFA).

MATERIALS AND METHODS

A total of 5 patients underwent surgery – 4 with chronic otitis media and 1 with otosclerosis (Tab. I.).

Surgical Technique

A combined approach to the tympanic cavity was used to perform intraoperative measurements. A postauricular incision was made. The mastoid surface was then exposed, and antromastoidectomy and posterior tympanotomy were performed, identifying the facial nerve. In cases of a pathology in the epitympanum, a posterior epitympanotomy was performed. Opening the mastoid antrum, posterior tympanotomy, and posterior epitympanotomy were used to clean the middle ear space of pathological changes. In case of revision stapedectomy, where the initial procedure revealed obliterative otosclerosis and the facial nerve completely overhanging the oval window, temporary transposition of the VIIth nerve was performed in the tympanic and mastoid segments. This allowed for the subsequent stages of stapedectomy: removal of the stapes suprastructure, fenestration in the stapes footplate, and visualisation of the inserted stapes prosthesis.

The incision of the skin of the posterior wall of the external auditory canal (EAC) was made high above the cartilage portion of the EAC, resting the knife on the edge of the posterior wall of the EAC and directing it approximately 45° downward. The horizontal incision was made at half the circumference and was located approximately 2 mm below the bony edge of the EAC. This facilitated the insertion of a microphone through the posterior skin meatotomy without disturbing the pinna position. The microphone in the EAC was sealed with oxicel strips. The tympanic membrane was reconstructed by harvesting the conchal perichondrium. The area of the harvested perichondrium exceeded 1 cm^3. The graft was pressed and dried, then adjusted to the defect. The perichondrium was placed by the underlay technique, and anteriorly, the graft was stabilised by the anterior tucking method, and the tympanomeatal flap was reposited back by placing the fibrous annulus back into the bony annulus, securing the graft.

Anterior fixation of the graft ensured proper tension of the anterior part and the correct shape of the reconstructed tympanic membrane. Perforations in the superior-anterior quadrant were additionally reconstructed by resting the graft on the lateral wall of the attic anterior to the head of the malleus. The graft position allowed for tight closure of the tympanic cavity in each case. A strip of a perforated silicone sheet was placed over the reconstruction, allowing for suction of excess blood immediately before microphone insertion and for possible EAC toiletting during measurements after temporary microphone removal.

Prosthesis insertion was performed in each case via posterior tympanotomy (Fig. 1).

In cases of chronic otitis, malleus footplate assembly reconstructions were performed using the cortical bone or incus (Fig. 2.).

In cases of otosclerosis, a “piston” prosthesis with a platinum wire clumping on to the long process of the incus was inserted. Corrections of the ossicular position were performed via posterior tympanotomy.

Once the prosthesis insertion is done and the graft is placed, after which the tympanomeatal flap is reposited back, the microphone with its sterile covering is placed in the EAC, and an active electrode is placed at the round window for the response to be recorded.

Measurement procedure

Multi-frequency ASSR recordings were obtained using the OssiMon research software interface based on the ASSR software and hardware platform developed by Intelligent Hearing Systems, Corp. (Miami, Florida, USA). A complex acoustic stimulus with a duration of 1 second was used, consisting of four carrier frequencies (500, 1000, 2000, and 4000 Hz) sampled at 20kHz. The stimulus was

Tab. II. Preoperative and postoperative PTA of each patient, recorded for frequency 250, 500, 1000, 2000, and 4000 Hz, showing air conduction (AC) and bone conduction (BC).

PATIENT NO.	LEFT(L) RIGHT(R)	AC	PTA AC FREQUENCY IN HZ						BC	PTA BC FREQUENCY IN HZ					
			250	500	1000	2000	3000	4000		250	500	1000	2000	3000	4000
1	L	Pre	100	110	115	95	100	105	Pre	50	55	65	55	65	75
		Post	75	80	85	75	65	80	Post	N.R	45	60	60	75	75
2	R	Pre	55	65	60	50	55	65	Pre	5	40	30	25	30	45
		Post	60	65	50	35	30	35	Post	10	25	30	25	25	30
3	R	Pre	55	60	75	50	45	65	Pre	5	10	20	20	15	35
		Post	55	70	40	40	30	40	Post	5	25	10	10	10	15
4	L	Pre	65	55	50	70	65	75	Pre	10	0	0	15	10	20
		Post	35	30	25	30	30	40	Post	5	0	0	10	10	20
5	R	Pre	85	90	90	90	100	120	Pre	30	40	50	65	70	80
		Post	60	60	60	55	70	85	Post	10	20	40	50	65	80

*N.R. – Non-recordable for that frequency

delivered to the monitored ear as a repeating sequence gated (RSG) tone for each carrier frequency, with modulation frequencies of 77, 85, 93, and 101 Hz for the left ear and 79, 87, 95, and 103 Hz for the right ear, respectively.

Acoustic stimulation was presented at various intensity levels, starting from 90 dB SPL and gradually decreasing to the auditory threshold in 10 dB steps. Response recordings were obtained using band-pass filtering with high-pass and low-pass cutoff frequencies of 30 Hz and 300 Hz, respectively, as well as a 50 Hz notch filter to suppress power line interference. An amplifier gain of 100,000 was applied for all recordings [1, 4] (Fig. 3.).

Prosthesis fitting procedure

If the conductive hearing improvement was not achieved, the prosthesis angulation was rechecked and reoriented, and again ASSR was repeated, and once an adequate ABG closure was achieved and recorded, closure was done. A pure tone audiometry was done at 3 months to know the status of the reconstructive surgery. The data of all 5 patients was compiled and analysed with an MS Excel sheet 2007 (Tab. II.).

RESULTS

Four patients underwent ossicular reconstruction and one stapedectomy. Each patient's detailed preoperative and postoperative results in each frequency are shown in Tab. II. The preoperative, postoperative, and intraoperative air-bone gap of each patient across frequencies 500, 1000, 2000, and 4000 Hz are shown in Tab. III.

In patient no. 1, the mean ABG preoperative was 43.75 dB, intraoperative ABG – 28.75 dB, and postoperative (after 3 months) – 20 dB, which showed 23.75 dB improvement (Fig. 4.–6.).

Patient 2 had the mean ABG preoperative of 25 dB, with intraoperative ABG of 7.75 dB. Postoperative ABG was 18.75, meaning an improvement of 6.25 dB. In this case, despite changing the position of the prosthesis, measurements did not confirm better improvement.



Fig. 2. Reshaped remnant of the incus used as a prosthesis for malleus footplate assembly.

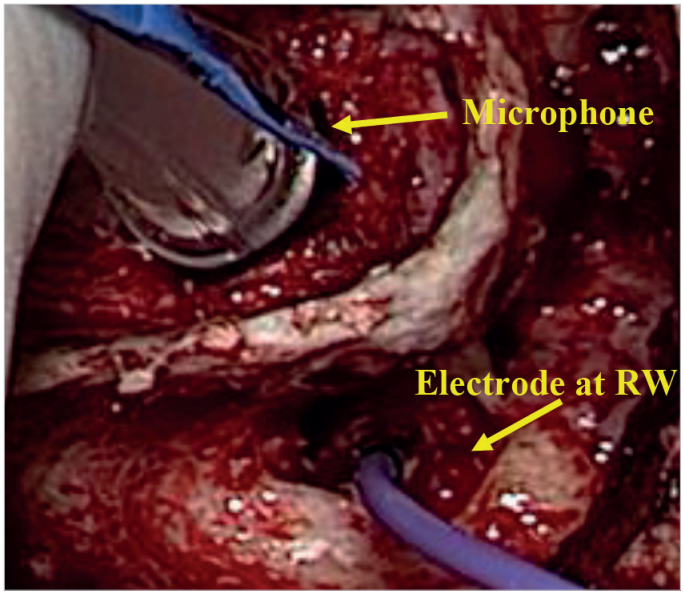

Fig. 3. Left ear – Recording electrode placed at the round window and a microphone placed in the EAC after placing a perforated silicone sheet over the reconstructed tympanic membrane.

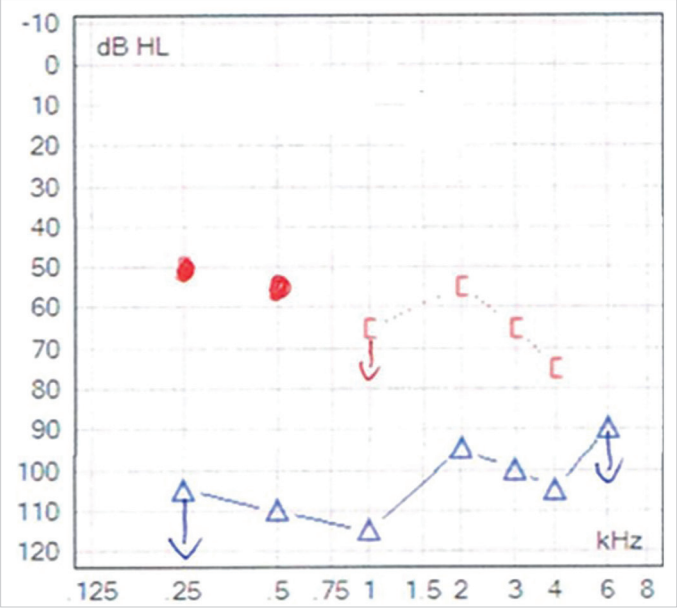

Fig. 4. Right ear – Preoperative pure tone audiogram of patient no. 1.

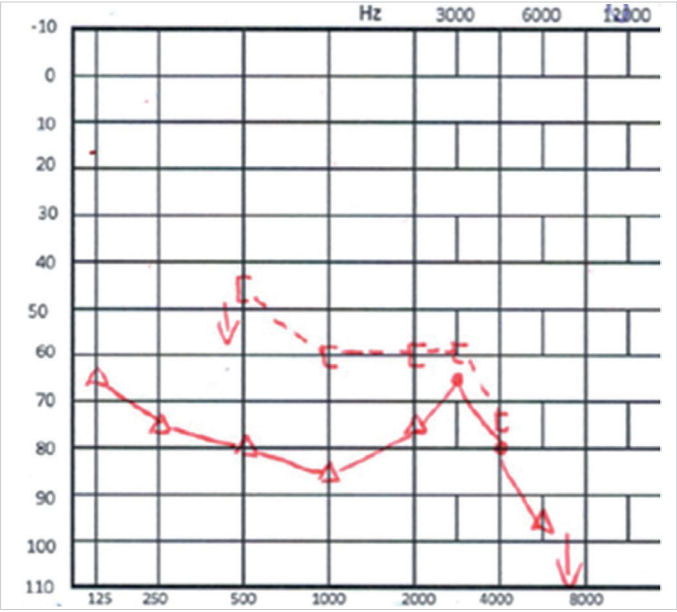

Fig. 5. Right ear – Postoperative pure tone audiogram conducted after 3 months in patient no. 1.

In patient 3, the mean ABG preoperative was 41.25 dB, intraoperative ABG was 3.5 dB and postoperative ABG was 32,5 dB, again showed improvement of 8.75 dB. In this case in subjective evaluation a patient confirmed gradual worsening of hearing with time.

In patient 4, the mean ABG preoperative was 53.75 dB, intraoperative ABG was 41.5 dB, and postoperative ABG was 23.75 dB, with an improvement of 29.75 dB.

In patient 5, the mean ABG preoperative was 38.75, and intraoperative ABG was 18.5, while postoperative ABG was 17.5 and showed an improvement of 21.25.

Patients 1, 4, and 5 had a significant improvement in their ABG, i.e. of more than 20 dB, which is clinically significant, whereas patients 2 and 3 also showed an improvement in their ABG, but of less than 20 dB.

Tab. III. Mean air-bone gap in preoperative, intraoperative, and post-operative assessment of 500, 1000, 2000, and 4000 Hz.

PATIENT NO.	ABG PRE	ABG INTRAOPERATIVE	ABG POST
1	43.75	28.75	20
2	25	7.75	18.75
3	41.25	3.5	32.5
4	53.75	41.5	23.75
5	38.75	18.5	17.5

Tab. IV. The mean level of the air curve in the study group across all frequencies during the preoperative period in intraoperative and post-operative assessment.

	PRE-AC (PTA)	INTRAOPERATIVE AC (ASSR)	POST-AC (PTA)
Mean (dB)	77.75	55.9	54.0

Tab. IV. shows the collected data of the mean air conduction of 5 patients. This value was preoperatively at a level of 77.75 dB and intraoperatively (assessed by ASSR) – 55.9 dB, which correlates with the postoperative value – of 54.0 dB.

We have stated that the difference between the mean postoperative ABG and the mean intraoperative ABG at 1000 Hz, 2000 Hz, and 4000 Hz was respectively 3 dB, 4 dB, and 7 dB, whereas the difference at 500 Hz was 16 dB. (Tab. V.). It showed that at higher frequencies, the intraoperative ABG and postoperative ABG correlation is better than at lower frequencies. But even at a lower frequency, the difference was less than 20 dB.

DISCUSSION

Intraoperative hearing monitoring in conductive hearing loss can be applied for all cases requiring ossiculoplasty to assess the good positioning of the ossicular prosthesis, allowing a good coupling with the residual ossicles to achieve an adequate postoperative functional hearing outcome. Niemczyk et al. in their 2018 study assessed the efficacy of ASSR with LDV in ossiculoplasty, but in the second-stage surgeries [1]. In our study, we conducted the intraoperative monitoring with ASSR only, and in one-stage surgery with posterior tympanotomy (PT), allowing for easy access to the middle ear for ossiculoplasty as well as tympanic membrane reconstruction, where required, without disturbing the EAC. A imilar approach with measurements was applied in case of stapedectomy. Despite it being a very difficult case, necessitating temporary transposition of the facial nerve, placement of the prosthesis and other manipulation for hearing reconstruction were performed with posterior tympanotomy. Martin et al. [18] were the first to advocate for posterior tympanotomy as a working approach in one-stage cholesteatoma clearance and ossiculoplasty. In our study, this approach, along with disease clearance and ossiculoplasty, enables and simplifies the intraoperative ASSR assessment as well. Placing a recording electrode close to the cochlea allows for getting good-quality ASSR.

The preliminary study on modified ASSR by Cui et al. showed that compared to ABR, as another option for intraoperative monitoring,

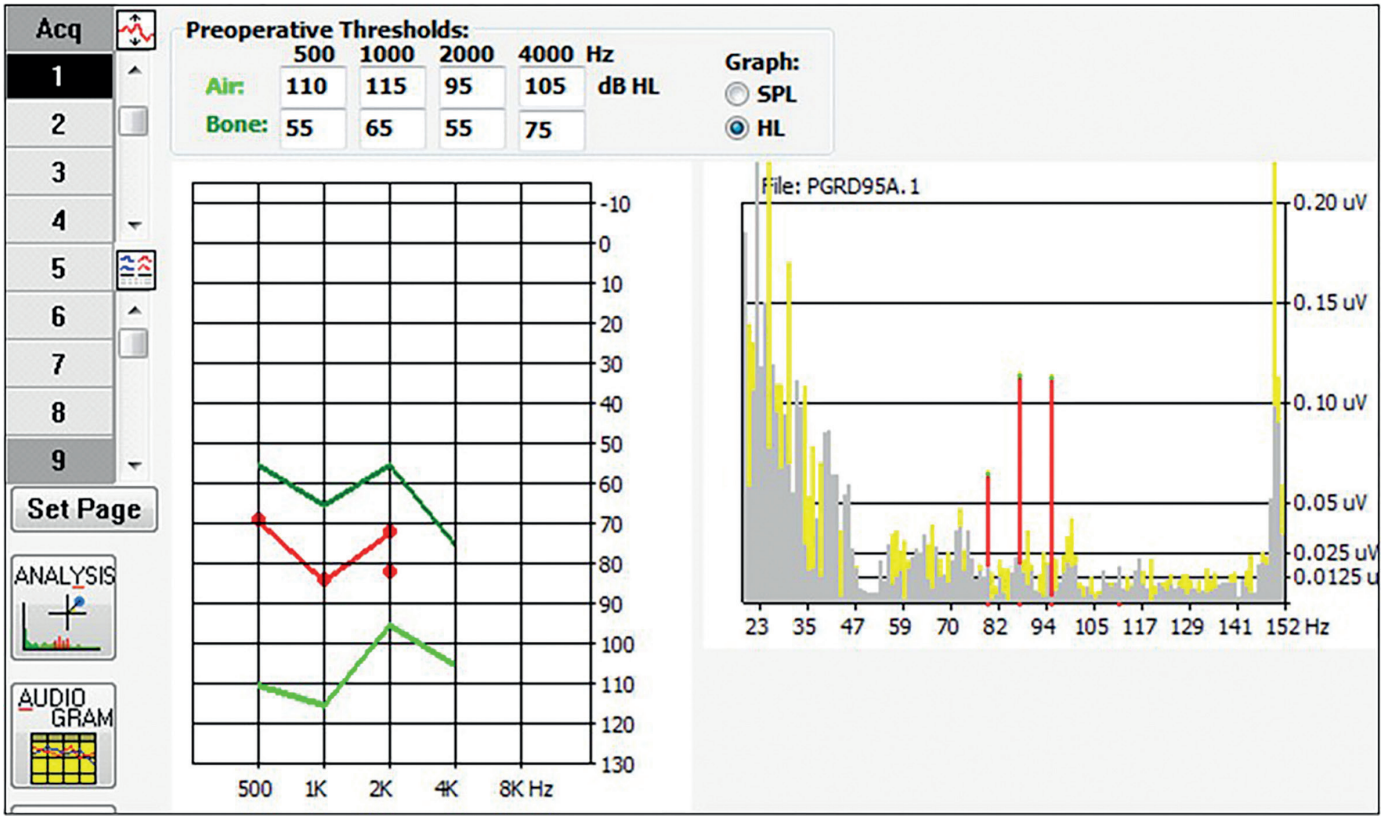

Fig. 6. Right ear, patient no. 1 – Intraoperative ASSR showing ABG closure at 500, 1, 2, and 4 KHz. The dark green line shows the pre-operative bone conduction, the light green line represents the air conduction preoperatively, and the superimposed auditory steady-state response (ASSR) indicators (red filled circles) and ASSR audiogram thresholds (red line) after optimal prosthesis placement, showing 15 dB air-bone gap. Upper right side: spectral display for ASSR recording at 95 dB SPL showing responses at 500, 1000, and 2000 Hz.

Tab. V. Mean air-bone gap (ABG) in preoperative and postoperative ABG closure, and intraoperatively, in the most appropriate position, seen at frequencies 500, 1000, 2000, and 4000 Hz.

FREQUENCY	PTA PRE ABG [DB]	PTA POST ABG [DB]	INTRAOPERATIVE ABG IN THE BEST POSITION OF THE PROSTHESIS [DB]
	Mean	Mean	Mean
500	47	38	31
1000	45	24	20
2000	35	16	19
4000	35	12	28

ASSR proves to be the best choice as it is characterized by better frequency specificity, shorter test times, simultaneous monitoring of full-frequency thresholds, automatic interpretation of test results, and avoidance of subjective errors. In the same study, they assessed the need for intraoperative contralateral ear masking, and showed no significant difference between intraoperative ASSR and postoperative ABG at 1, 2, and 4 kHz, and hence no need for masking of the opposite ear [19].

Nguyen et al. [20] devised a handheld probe which uses a piezoelectric sensor that can be used on intact ossicles and each ossicle based on the type of ossiculoplasty, and compared it with LDV measurements and proved to be equally accurate.

Similarly, Zehnert et al. [21, 22] replaced the piezoelectric stimulation with acoustic stimulation and measured it with LDV, creating a middle ear transfer function (METF) which did not require an intact tympanic membrane as the stimulation was given the umbo and at 70 dB and 80 dB.

Finally, Liu et al. [20] combined chirp-ASSR with a self-designed sound field earphone (SFE), and they obtained multi-frequency intraoperative auditory thresholds, which can also be used in intraoperative ossiculoplasty assessment. These 3 studies show the future implications of using combined techniques to obtain accurate and easily implementable intraoperative ossicular measurements to predict the postoperative hearing thresholds similar to the objective of this study [3, 20–22].

In our study, we confirmed the feasibility of intraoperative ASSR in one-stage reconstruction of conductive hearing loss. In addition, the intra-operative measurements correlated with postoperative ABG closure.

The limitations of our study were:

1. The cohort size of our study was not significant, so it was only an observational study;
2. The role of postoperative healing impacting the hearing loss is yet to be understood;
3. The long-term results, that is postoperative PTA after 1 year compared to intraoperative ASSR, are yet to be collected and analyzed.

CONCLUSIONS

Intraoperative hearing monitoring using ASSR during one-stage tympanoplasty is a promising and effective method for functional evaluation of ossiculoplasty. ASSR correlates reliably with audiometric findings and allows for optimization of surgical techniques in real time. Further studies are required to standardize the methodology and implement it widely in clinical practice.

REFERENCES

1. Niemczyk K., Morawski K., Delgado R., Bruzgielewicz A., Lachowska M.: Objective assessment of hearing during second stage of tympanoplasty-surgical technique and measurement methodology presented in ten patients. Clin Otolaryngol., 2018; 43(1): 347–352.
2. Kotzias S.A., Seerig M.M., Mello M.F.P.C., Chueiri L., Jacques J. et al.: Ossicular chain reconstruction in chronic otitis media: hearing results and analysis of prognostic factors. Braz J Otorhinolaryngol., 2020; 86(1): 49–55.
3. Nguyen V.S., Rouxel D., Vincent B., Ducourneau J., Parietti-Winkler C.: A new device for real-time peroperative monitoring of ossicular chain reconstruction during middle ear surgery. J Clin Monit Comput., 2019; 34(4): 827–832.
4. Niemczyk K., Pobożny I., Bartoszewicz R., Morawski K.: Intraoperative Hearing Monitoring Using ABR and TT-ECochG and Hearing Preservation during Vestibular Schwannoma Resection. J Clin Med., 2024; 13(14): 4230.
5. Alosaimi A., Abulfateh F.N., Bedawi F.K., Aljeeb A.M., Sabra O.A.: Comparison of Hearing Outcomes in Tympanoplasty With and Without Ossiculoplasty: A Retrospective Cohort Study. Cureus., 2024; 16(11) :e73924.
6. Lim J.H., Park J.M., Han J.J., Kim S.I., Park S.Y. et.al.: Superiority of Second Stage Ossiculoplasty. Otol Neurotol., 2018; 39(10): 1271–1276.
7. Sprinzl G.M., Schörg P., Edlinger S., Ploder M., Magele A.: Clinical feasibility of a novel test setup for objective measurements using the VIBRANT SOUNDBRIDGE. Laryngoscope Investig Otolaryngol., 2022; 7(4): 1113–1119.
8. Morawski K., Niemczyk K., Sokolowski J., Hryciuk A., Bartoszewicz R.: Intraoperative Monitoring of Hearing Improvement during Ossiculoplasty by Laser-Doppler Vibrometry, Auditory Brainstem Responses, and Electrocochleography. Otolaryngol Head Neck Surg., 2014; 150(6): 1043–1047.
9. Backous D., Choi B.Y., Jaramillo R. et.al.: Hearing Rehabilitation of Patients with Chronic Otitis Media: A Discussion of Current State of Knowledge and Research Priorities. J Int Adv Otol., 2022; 18(4): 365–370.
10. Rampp S., Stavrakakis S., Kunkel D. et al.: Intraoperative auditory steady-state monitoring during surgery. J Neurosurg., 2016; 127(3): 559–566.
11. Ren W., Ji F., Zeng J., Zhao H.: Intra-operative hearing monitoring methods in middle ear surgeries. J Otol., 2016; 11(4): 178–184.
12. Cebulla M., Köstler C., Herrmann D.P., Rak K.: Intraoperative ABR measurements via the active middle ear implant Vibrant Soundbridge using different types of couplers. Eur Arch Oto-Rhino-Laryngol., 2025; 282: 3507–3512.
13. Morawski K., Niemczyk K., Delgado R.E.: Combined model of intraoperative monitoring of ossiculoplasty efficiency by laser-Doppler vibrometry and auditory evoked potentials. The Journal of Laryngology & Otology. 2016; 130: S16–S17.
14. Müller C, Lailach S, Bornitz M., Lasurashvili N., Essinger T.M. et al.: Influence of coupling on hearing outcome after implantation of an active middle ear implant: comparison of transmission behavior in temporal bone experiments with clinical data. Ear & Hearing., 2023; 44(1): 135–145.
15. Sokołowski J., Lachowska M., Bartoszewicz R., Niemczyk K.: Methodology forIntraoperative Laser Doppler Vibrometry Measurements of Ossicular Chain Reconstruction. Clin Exp Otorhinolaryngol., 2016; 9(2): 98–103.
16. Verhaegen V.J., Mulder J.J.S., Noten J.F.P., Luijten B.M.A., Cremers C.W.R.J. et.al.: Intraoperative Auditory Steady State Response Measurements During Vibrant Soundbridge Middle Ear Implantation in Patients With Mixed Hearing Loss: Preliminary Results. Otology & Neurotology., 2010; 31(9): 1365–1368.
17. Radeloff A., Shehata-Dieler W., Rak K., Scherzed A., Tolsdorff B. et al.: Intraoperative monitoring of active middle ear implant function in patients with normal and pathologic middle ears. Otol Neurotol., 2011; 32: 104–107.
18. Martin C., Prades J.M., Richard C.: Ossiculoplasty positioned via posterior tympanotomy. Eur Ann Otorhinolaryngol Head Neck Dis., 2012; 129(4): 220–222.
19. Cui B., He W., Feng T., Huang W., Feng Y. et al.: Optimizing Intraoperative Hearing Monitoring in Middle Ear Surgeries: A Preliminary Study of the Modified Auditory Steady-State Responses Measurement Method With Different Electrode Placement and Masking. Otol Neurotol., 2026; 7(2): 227–234. doi: 10.1097/MAO.0000000000004754.
20. Liu Q., Feng G., Shang Y., Chi C., Qiao Y. et al.: Threshold monitoring of intraoperative auditory steady-state responses for ossiculoplasty surgery. Acta Otolaryngol., 2018; 138(7): 625–632.
21. Müller C., Polk M.L., Lorenz K., Bornitz M., Zahnert T. et al.: Real-time monitoring of middle ear prosthesis coupling. Hear Res., 2023; 432: 108737.
22. Zahnert T., Metasch M.L., Seidler H., Bornitz M., Lasurashvili N. et al.: A New Intraoperative Real-time Monitoring System for Reconstructive Middle Ear Surgery: An Experimental and Clinical Feasibility Study. Otol Neurotol., 2016; 37(10): 1601–1607.

Table of content: https://otorhinolaryngologypl.com/issue/17010 Tables: 5 Figures: 6 References: 22

Copyright: Some rights reserved: Polish Society of Otorhinolaryngologists Head and Neck Surgeons. Published by Index Copernicus Sp. z o.o.

Competing interests: The authors declare that they have no competing interests.

The content of the journal „Polish Society of Otorhinolaryngologists Head and Neck Surgeons" is circulated on the basis of the Open Access which means free and limitless access to scientific data.

This material is available under the Creative Commons – Attribution-NonCommercial 4.0 International (CC BY-NC 4.0).
The full terms of this license are available on: https://creativecommons.org/licenses/by-nc/4.0/legalcode

Corresponding author: Askhat Khamidulin (ORCID: 0009-0000-5136-075X); Department of Otorhinolaryngology, Head and Neck Surgery, Medical University of Warsaw; Warsaw, Poland; E-mail: asxat070785xan@gmail.com

Cite this article as: Khamidulin A., Kamath A., Bartoszewicz R., Niemczyk K.: Feasibility of Hearing Monitoring using ASSR during one Stage Tympanoplasty and Ossicular Chain Reconstruction – preliminary report; Pol Otorhino Rev 2025; 14 (4): 30–37; DOI: 10.5604/01.3001.0055.5058